

## Research Article

## Open Access



## ***Hibiscus rosa sinensis* L. anthocyanins prevent lipid peroxidation and improve antioxidant status in the liver of streptozotocin-induced diabetic rats**

**Velappan Nair Saralakumari Kalpana<sup>1</sup>, Jincy Mary<sup>1</sup>, Saraswathy Mini<sup>1\*</sup>, Neelakanta Pillai Padmakumari Soumya<sup>1</sup>, Sukanta Mondal<sup>2</sup>**

<sup>1</sup>Department of Biochemistry, University of Kerala, Karyavattom Campus, Thiruvananthapuram, India; <sup>2</sup>ICAR-National Institute of Animal Nutrition and Physiology, Bengaluru, India

**\*Corresponding Author:** Dr. Saraswathy Mini, Professor, Department of Biochemistry, University of Kerala, Karyavattom Campus, Salem - Kochi - Kanyakumari Hwy, Karyavattom, Thiruvananthapuram, Kerala 695581, India

**Submission Date:** September 7<sup>th</sup>, 2021; **Acceptance Date:** October 22<sup>nd</sup>, 2021; **Publication Date:** October 28<sup>th</sup>, 2021

**Please cite this as:** Kalpana V.S., Mary J., Mini S., Soumya N.P., Mondal S. *Hibiscus rosa sinensis* L. anthocyanins prevent lipid peroxidation and improve antioxidant status in the liver of streptozotocin-induced diabetic rats. *Bioactive Compounds in Health and Disease* 2021; 4(10): 240-255. DOI: <https://www.doi.org/10.31989/bchd.v4i10.842>

### **ABSTRACT:**

**Background:** Hyperglycemia and oxidative stress are hallmarks of diabetes mellitus (DM). Excessive oxidative stress is implicated in diabetic pathogenesis when endogenous antioxidants are defective.

**Objective:** The present study evaluates the effects of anthocyanins present in the petals of *Hibiscus rosa-sinensis* on oxidative stress and antioxidant status in streptozotocin-induced diabetic rats.

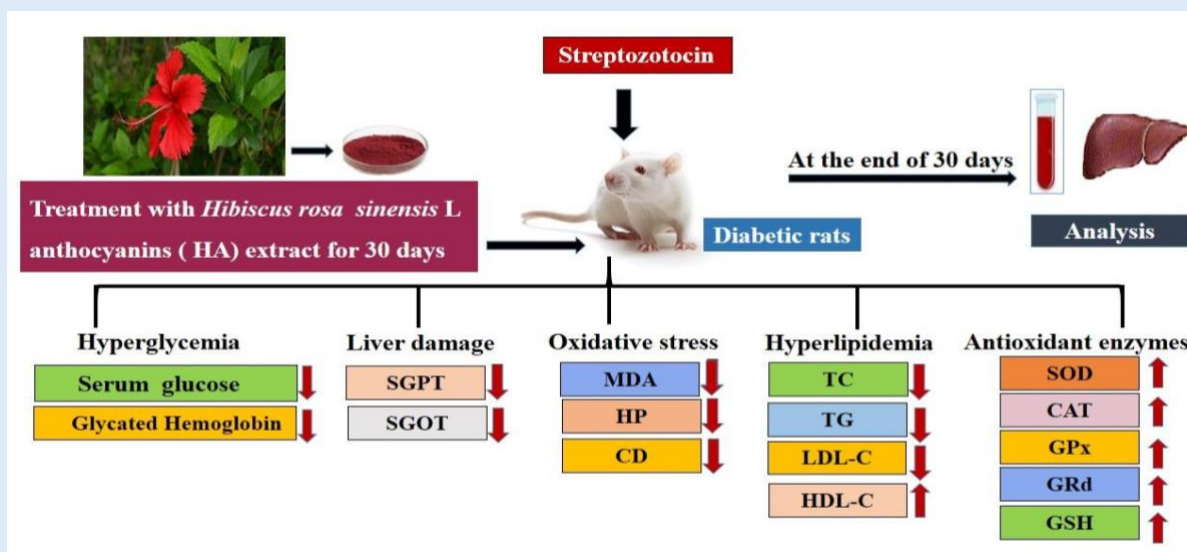
**Materials and methods:** Diabetes was induced in male Sprague-Dawley rats by a single intraperitoneal injection (30mg/kg) of streptozotocin. *Hibiscus rosa sinensis* anthocyanins (HA) extract (50 mg/kg body weight) orally administered to diabetic rats for 30 days. Results compared with diabetic rats provided with the standard drug metformin (150 mg/kg body weight).

**Results:** Altered levels of glucose, glycated hemoglobin, toxicity markers and lipid profile in serum were significantly modulated upon the administration of HA in diabetic rats. A supplementation of HA to diabetic rats reduced

oxidative stress, as well as increased the levels of antioxidant enzymes in the liver. The present study demonstrates that HA has a protective effect on diabetic rats

**Conclusion:** The present study indicates that Hibiscus anthocyanin supplementation could protect diabetic rats' livers by protecting the hepatocytes from oxidative stress and increasing the antioxidant enzymes' activity.

**Keywords:** Diabetes mellitus, *Hibiscus rosa sinensis* anthocyanins, Oxidative stress



©FFC 2021. This is an Open Access article distributed under the terms of the Creative Commons Attribution 4.0 License (<http://creativecommons.org/licenses/by/4.0>)

## INTRODUCTION

Diabetes mellitus (DM) is a group of metabolic disorders characterized by hyperglycemia, caused by impaired insulin production by pancreatic beta-cells and insulin resistance in peripheral tissues [1]. Oxidative stress is the imbalance between the generation of free radicals and the antioxidant defense system [2]. Persistent hyperglycemia in diabetes results in the production of reactive oxygen species (ROS) through the activation of several pathways like glyceraldehyde autoxidation, methylglyoxal glycation, protein kinase C (PKC) activation, hexosamine pathways, and oxidative phosphorylation [3]. The liver is one of the tissues

susceptible to oxidative stress. Studies have shown that the main sources of free radicals in hepatic tissue are mitochondria and cytochrome P450 enzymes. Previous studies suggest that oxidative stress contributes to hepatic complications [4]. Generally, oxidative stress leads to oxidation and damage of macromolecules involved in energy production (such as proteins, lipids, and enzymes) and is involved in the cellular injury, energy depletion, and acceleration of cell death through apoptosis and necrosis. Studies have demonstrated that oxidative stress increases lipid peroxidation and decreases antioxidant activity [5]. Superoxide dismutase (SOD), glutathione peroxidase (GPx), catalase (CAT), and reduced

glutathione (GSH) are antioxidants capable of scavenging free radicals by breaking down ROS [6]. Polyphenols are bioactive compounds in plants, fruits, and vegetables with antioxidant properties that have been shown to prevent diabetic complications caused by oxidative stress. [7].

***Hibiscus rosa sinensis* Linn.** (Malvaceae) is a shrub commonly found in the tropics of India. The plant is reported to possess hypoglycemic, cardioprotective, antitumor, anti-fertility, anti-inflammatory, hair growth-promoting, and antioxidant properties [8]. It is broadly used as an ingredient in herbal teas; its beneficial effects are attributed to the antioxidant phenolic compounds. The previous studies conducted in our lab revealed the protective role of flavonoid-rich ethyl acetate fraction of *Hibiscus rosa sinensis* flower petals in modulating glucose homeostasis and diabetic stress signaling pathways [9]. The red pigments in red flowers of the Hibiscus are the anthocyanins and have been widely used as coloring agents.

Anthocyanins (ACs) are water-soluble polyphenolic pigments and are referred to as flavonoids [10]. Anthocyanins are responsible for red-orange to blue-violet colors in various plants, especially purple cabbage, purple grapes, blueberries, cherries, black rice, flowers, fruits, and vegetables [11]. Anthocyanins are found as aglycon derivatives called anthocyanidins. Anthocyanidins, viz., cyanidin, delphinidin, malvidin, peonidin, pelargonidin, and petunidin, are predominantly found in nature [12]. The *in vitro*, *in vivo*, and clinical trial studies identified ACs as potent antioxidative compounds capable of preventing the progression of several chronic degenerative diseases related to ageing, oxidative stress, and inflammation, such as diabetes, cardiovascular diseases, or neurodegenerative diseases [13]. Animal studies showed that purified

anthocyanins and foods containing anthocyanins regulated glucose metabolism, enhanced insulin sensitivity, and improved  $\beta$  cell dysfunction in type 2 diabetes. Consumption of anthocyanins and anthocyanin-rich fruit was associated with a lower risk of type 2 diabetes in large cohort studies [14].

The present study investigates the beneficial protective effect of the anthocyanins present in the *Hibiscus rosa sinensis* flower petals on oxidative stress and antioxidant status in the hepatic tissue of streptozotocin-induced diabetic rats.

## MATERIALS AND METHODS

**Chemicals:** All Chemicals for the current study were purchased from SIGMA ALDRICH (St. Louis, MO, USA), MERCK Chemical Company (Darmstadt, Germany), and Sisco Research Laboratories (Mumbai, India).

**Preparation of Anthocyanin-rich extract from *Hibiscus rosa sinensis* flower petals:** *Hibiscus rosa sinensis* flowers were collected from Trivandrum, India. Authentication was done by Dr. G. Valsala Devi, Curator, Department of Botany, and the University of Kerala. For further reference, a voucher specimen (Voucher No. KUBH-5845) has been deposited in the herbarium, Department of Botany, the University of Kerala. The petals were shade dried and powdered, 10g of the petal powder weighed was soaked in 200 mL acidified methanol (0.1% HCl (v/v) in methanol) for 3 hours at room temperature in darkness [15]. The mixture was filtered in a Buchner funnel, and the remaining solids were washed with 0.1% HCl in methanol until a clear solution was obtained. The combined filtrates were dried using a rotary evaporator at 55°C. The dried extract was dissolved in water and used for the present study. Figure 1 shows an image of the *Hibiscus rosa sinensis* flower.



**Figure 1:** *Hibiscus rosa sinensis* flower

**Detection of Total Anthocyanin content:**

Anthocyanin analysis was performed using a UV-visible spectrophotometric pH differential method [16-17].

**Experimental animals:** Male albino rats (Sprague-Dawley) of body weight 200 – 250 g were used for the study. They were provided with Laboratory chow (Hindustan Lever Lab diet) and water *ad libitum* throughout the experimental period. The rats were housed in polypropylene cages in a room with temperature maintained at  $26 \pm 1^{\circ}$  C and a 12 hour light and dark cycle. The institutional animal ethics committee approved all experimental protocols (IAEC-KU-11/2013-14- BC- SM (19)).

**Induction of experimental diabetes:** Diabetes was induced in rats by a single intraperitoneal injection of freshly prepared STZ at a 30 mg/kg body weight dose in 0.1M citrate buffer (pH 4.5) [18]. The animals were allowed to drink 5% glucose solution overnight to overcome the drug-induced hypoglycemia. The animals with blood glucose levels between 200 mg/dL and 400 mg/dL are considered diabetic.

**Experimental design:** The oral toxicity study was performed as per OECD guidelines 420. It was previously performed in our laboratory using three different doses of HA (50 mg/ kg body weight, 100

mg/kg body weight, and 200 mg/kg body weight). The extract at an optimal dose of 50 mg/kg body weight was effective and safe compared with the other two doses (100 mg/kg body weight and 200 mg/kg body weight). Therefore, the optimum dose of HA was used for the present study. Analyses of the *Hibiscus rosa sinensis* flower petals extract revealed the presence of 0.35gm% anthocyanins. Diabetes was induced in rats by a single intraperitoneal injection of freshly prepared STZ at a dose of 30 mg/kg body weight. Diabetic rats were supplemented with Hibiscus anthocyanins (50mg/ kg body weight) by gastric intubation for 30 days. The experimental animals were divided into five groups of six rats each. The effect was compared with the antidiabetic drug Metformin.

Group 1: Normal control rats (N)

Group 2: Normal rats treated with HA (50 mg/Kg body weight) (N + HA)

Group 3: Diabetic control rats (D)

Group 4: Diabetic rats treated with HA (50 mg/Kg body weight) (D+ HA)

Group 5: Diabetic rats treated with Metformin (150 mg/Kg body weight) (D+M)

During the experimental period, the body weight and blood glucose of the rats were monitored at definite intervals. Dosage of the extract and standard drugs were maintained in accordance with the change in body weight of the rats throughout the study period. After 30 days, the rats were sacrificed, and blood and liver were collected for various biochemical analyses.

**Biochemical parameters:** Serum glucose was estimated by the glucose oxidase method described by [19]. The amount of glycated hemoglobin (HbA1c) was quantified by using the HbA1c kit (Beacon Diagnostics Pvt. Ltd). Total cholesterol (TC),

Triglycerides (TG), High-density lipoprotein - cholesterol (HDL-C), and Low-density lipoprotein cholesterol (LDL-C) were determined using AGAPPE diagnostics kits (AGAPPE Diagnostics Limited, Ernakulam, Kerala). Serum Glutamate Pyruvate Transaminase (SGPT) and Serum Glutamate Oxaloacetate Transaminase (SGOT) were assayed using the enzyme kit from CML Biotech (P) Ltd, Ernakulam, India, described by [20]. The protocol of [21] determined the activity of catalase (CAT), and the superoxide dismutase (SOD) activity was measured by the method of [22]. The protocol of [23] evaluated the activity of Glutathione peroxidase (GPx), glutathione reductase (GRd) activity by the procedure of [24]. The glutathione content (GSH) was analyzed by the procedure given by [25]. Thiobarbituric acid reactive substances (TBARS) were estimated by the method of [26]. Hydroperoxides (HP) and conjugated dienes (CD) were estimated by the method of [27]. Protein was estimated according to the method of [28] respectively.

**Statistical analysis:** Values were expressed as mean  $\pm$  SD. Statistical analyses were performed by one-way ANOVA using SPSS version 17 (SPSS, Inc., Chicago, IL, USA). Duncan's post hoc multiple-comparison tests were used to determine significant differences among groups.  $p < 0.05$  was considered to be significant.

## RESULTS

**Total Anthocyanin content:** Anthocyanin analyses of the *Hibiscus rosa sinensis* flower petals extract revealed the presence of 0.35 gm% anthocyanins.

**Change in body weight:** In the present study, the average body weight of the rats was uniform at the beginning of the experiment. The body weights of rats were significantly diminished in STZ induced diabetic control rats when compared to normal control rats. However, HA or metformin supplementation significantly improved the bodyweight of diabetic rats when compared to diabetic control rats (Fig 2).

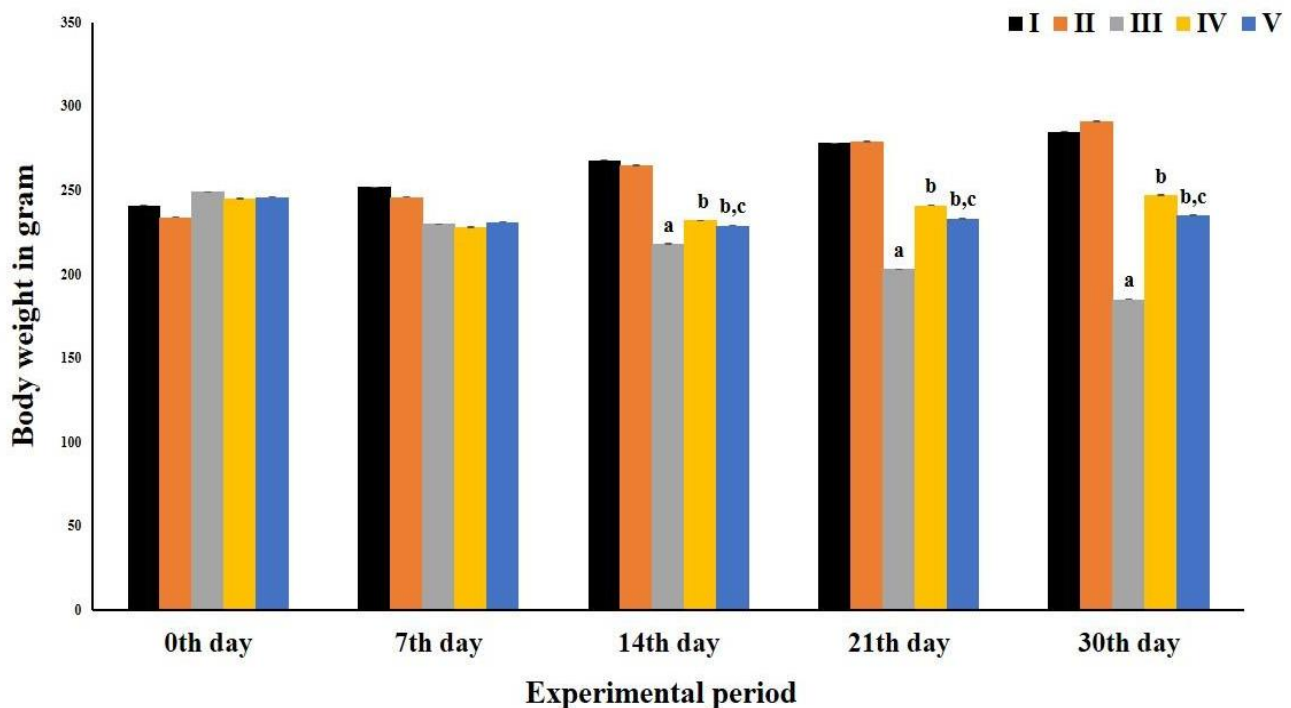


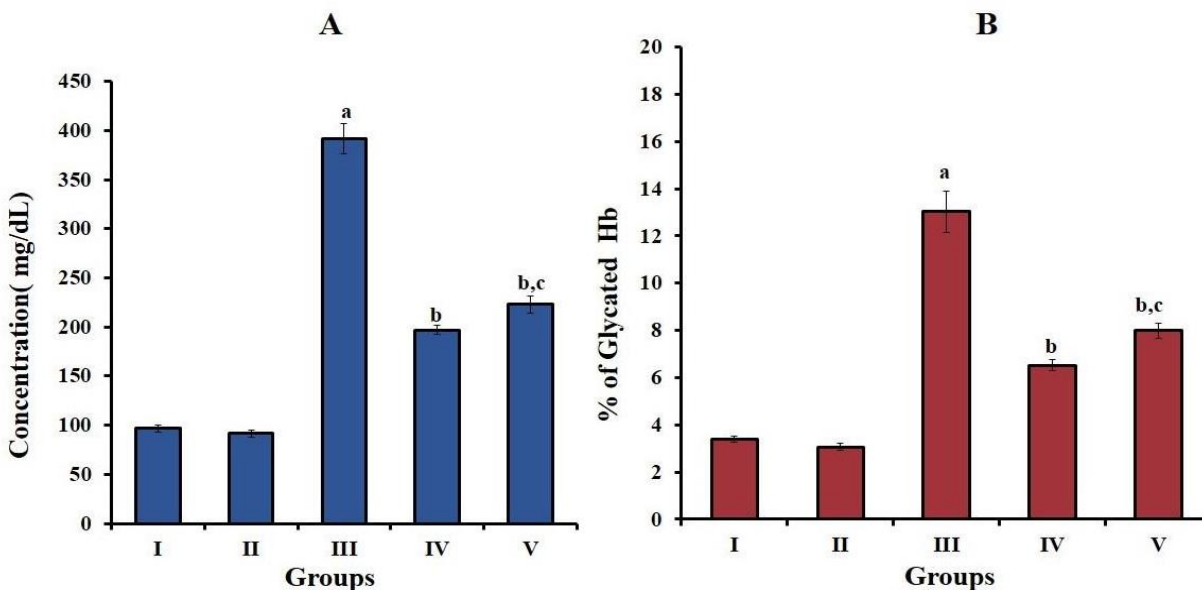
Figure 2. Change in body weigh

Values are expressed as mean  $\pm$  SD (n = 6). Group I: Normal control(N); Group II: Normal rats given 50 mg Hibiscus anthocyanin (HA) /kg body weight of rats (N+HA); Group III: Diabetic control (D); Group IV: Diabetic rats given 50 mg Hibiscus anthocyanin (HA)/kg body weight of rats (D+HA); V: Diabetic rats given 150 mg metformin/kg body weight of rats (D+M). 'a' indicates values significantly different from normal control groups. 'b' indicates values significantly differ from diabetic groups. 'c' indicates

values are significantly different from HA treated groups. Significance accepted at  $p < 0.05$ .

#### **Serum glucose and Glycated hemoglobin (HbA1c):**

Serum glucose (Figure 3A) and HbA1c levels (Figure 3B) were significantly elevated in diabetic control rats compared to normal control rats. The oral administration of HA or metformin significantly reduced serum glucose and HbA1c levels compared to diabetic control rats. However, oral administration of HA to normal rats didn't show any significant deviation in serum glucose and glycated hemoglobin.



**Figure 3.** Serum glucose and Glycated hemoglobin

A) Serum glucose. B) Glycated hemoglobin. Values are expressed as mean  $\pm$  SD (n = 6). Group I: Normal control(N); Group II: Normal rats given 50 mg Hibiscus anthocyanin (HA) /kg body weight of rats (N+HA); Group III: Diabetic control (D); Group IV: Diabetic rats given 50 mg Hibiscus anthocyanin (HA)/kg body weight of rats (D+HA); V: Diabetic rats given 150 mg metformin/kg body weight of rats (D+M). 'a' indicates values significantly different from normal control groups. 'b' indicates values significantly different from diabetic groups. 'c' indicates values are significantly different from HA treated groups. Significance accepted at  $p < 0.05$ .

**Serum toxicity markers:** Liver toxicity markers were assayed to assess the hepatic injury. The activities of serum glutamate pyruvate transaminase (SGPT) and serum glutamate oxaloacetate transaminase (SGOT)

were significantly raised in diabetic control rats compared to normal control rats. Supplementation of HA or metformin to diabetic rats significantly decreased the SGPT and SGOT activities compared with the diabetic control rats (Table 1).



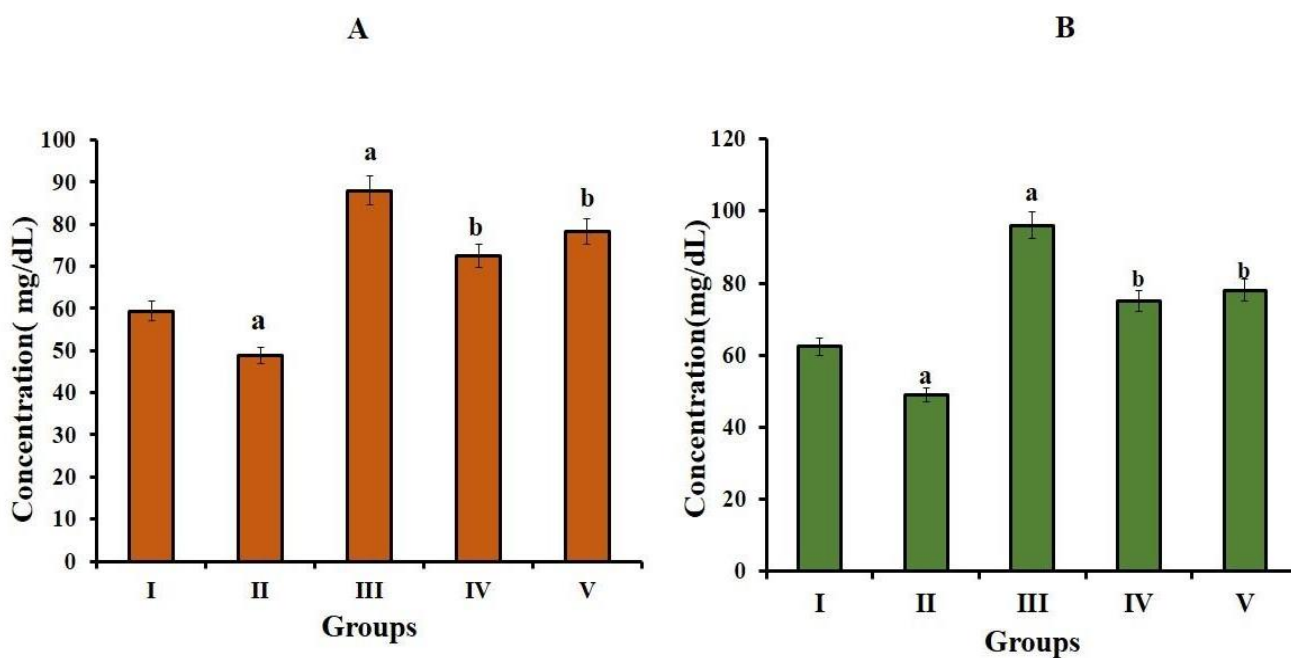
**Table 1:** Toxicity markers in serum

GROUPS	SGPT (U/L)	SGOT (U/L)
I	40.03 ± 3.83	33.43 ± 4.85
II	35.57± 3.07 <sup>a</sup>	29.33 ± 3.88 <sup>a</sup>
III	64.84 ± 6.21 <sup>a</sup>	48.26 ± 4.60 <sup>a</sup>
IV	47.09 ± 4.51 <sup>b</sup>	38.70 ± 3.70 <sup>b</sup>
V	48.46 ± 4.64 <sup>b</sup>	37.44 ±3.50 <sup>b</sup>

**Toxicity markers in serum:** Values are expressed as mean ± SD (n = 6). Group I: Normal control(N); Group II: Normal rats given 50 mg Hibiscus anthocyanin (HA)/kg body weight of rats (N+HA); Group III: Diabetic control (D); Group IV: Diabetic rats given 50 mg Hibiscus anthocyanin (HA)/kg body weight of rats (D+HA); V: Diabetic rats given 150 mg metformin/kg body weight of rats (D+M). 'a' indicates values significantly different from normal control groups. 'b'

indicates values significantly different from diabetic groups. Significance accepted at p<0.05.

**Total cholesterol (TC) and Triglycerides (TG) in serum:** The concentrations of total cholesterol (Figure 4A) and triglycerides (Figure 4B) in serum were increased significantly in diabetic control rats when compared to normal rats. HA or metformin supplementation reduces the concentrations of TC and TG in diabetic rats when compared to untreated diabetic rats.



**Figure 4.** Serum Total cholesterol and Triglycerides

A) Total cholesterol B) Triglycerides. Values are expressed as mean ± SD (n = 6). Group I: Normal control(N); Group II: Normal rats given 50 mg Hibiscus anthocyanin (HA) /kg body weight of rats (N+HA); Group III: Diabetic control (D); Group IV: Diabetic rats given 50 mg Hibiscus anthocyanin (HA)/kg body weight of rats (D+HA); V: Diabetic rats given 150 mg metformin/kg body weight of rats (D+M). 'a' indicates values significantly different from normal control groups. 'b' indicates values significantly different from diabetic groups.

**High-density lipoprotein (HDL) and Low-density lipoprotein (LDL) in serum:** The good cholesterol HDL was significantly decreased in diabetic control rats when compared to normal rats. HA or metformin administration significantly increased the level of HDL in diabetic rats (Figure 5A). The bad cholesterol, LDL in serum (Figure 5B), was increased significantly in diabetic rats compared to normal rats. But HA or metformin supplementation reduces the level of LDL in diabetic rats when compared to untreated diabetic rats.

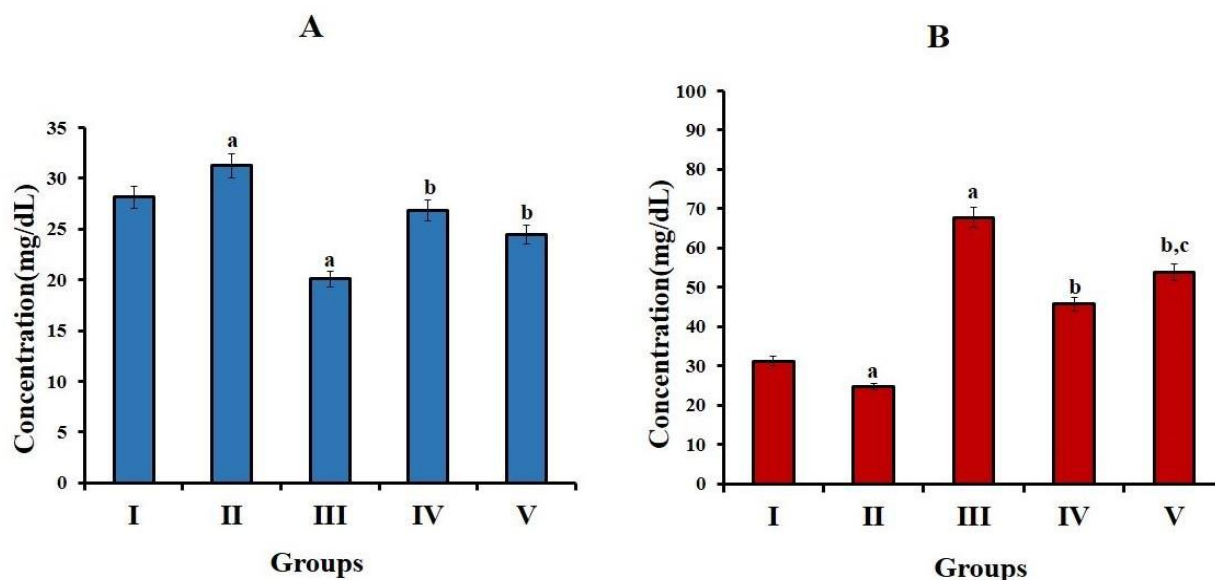


Figure 5. HDL in serum and LDL in serum

A) HDL in serum B) LDL in serum. Values are expressed as mean ± SD (n = 6). Group I: Normal control(N); Group II: Normal rats given 50 mg Hibiscus anthocyanin (HA) /kg body weight of rats (N+HA); Group III: Diabetic control (D); Group IV: Diabetic rats given 50 mg Hibiscus anthocyanin (HA)/kg body weight of rats (D+HA); V: Diabetic rats given 150 mg metformin/kg body weight of rats (D+M). 'a' indicates values significantly different from normal control groups. 'b' indicates values significantly different from diabetic groups. 'c' indicates values are significantly different from HA treated groups. Significance accepted at p<0.05.

**Hepatic antioxidant enzyme activities:** The activities of antioxidant enzymes superoxide dismutase (SOD), catalase (CAT), glutathione peroxidase (GPx), and glutathione reductase (GRd) were significantly diminished in diabetic control groups as compared to

normal control groups. While the inclusion of HA or metformin significantly enhanced the activities of antioxidant enzymes in the liver of diabetic rats (Table 2).



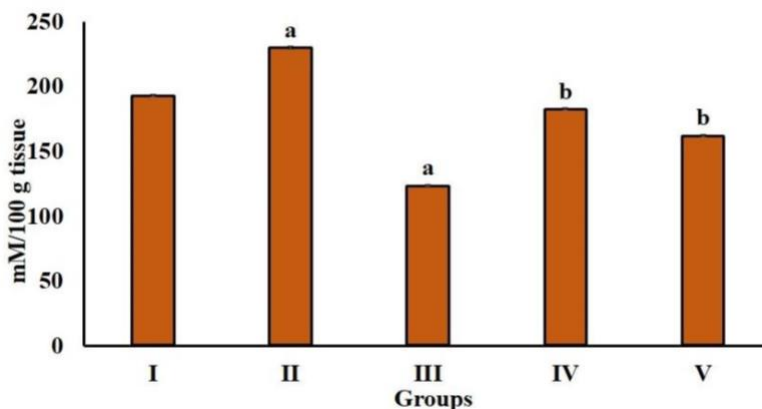
**Table 2:** Hepatic antioxidant enzyme activities:

GROUPS	CAT (10 <sup>-3</sup> U/mg protein)	GPx (U/mg protein)	GRd (U/mg protein)	SOD (U/mg protein)
I	6.04 ± 0.57	30.9 ± 2.96	21.4 ± 2.05	4.48 ± 0.43
II	7.70 ± 0.73 <sup>a</sup>	31.7 ± 3.04	25.1 ± 2.41 <sup>a</sup>	6.01 ± 0.57 <sup>a</sup>
III	3.11 ± 0.30 <sup>a</sup>	18.6 ± 1.78 <sup>a</sup>	13.6 ± 1.30 <sup>a</sup>	3.15 ± 0.30 <sup>a</sup>
IV	4.97 ± 0.47 <sup>b</sup>	27.1 ± 2.60 <sup>b</sup>	20.1 ± 1.90 <sup>b</sup>	4.19 ± 0.40 <sup>b</sup>
V	3.90 ± 0.37 <sup>b, c</sup>	23.1 ± 2.20 <sup>b, c</sup>	17.2 ± 1.65 <sup>b, c</sup>	3.70 ± 0.36 <sup>b</sup>

Values are expressed as mean ± SD (n = 6). Group I: Normal control(N); Group II: Normal rats given 50 mg Hibiscus anthocyanin (HA) /kg body weight of rats (N+HA); Group III: Diabetic control (D); Group IV: Diabetic rats given 50 mg Hibiscus anthocyanin (HA)/kg body weight of rats (D+HA); V: Diabetic rats given 150 mg metformin/kg body weight of rats (D+M). 'a' indicates values significantly differ from normal control groups. 'b' indicates values significantly different from diabetic groups. 'c' indicates values are significantly different from HA treated groups. Significance accepted at p<0.05.

**Reduced Glutathione content (GSH) in liver:** The concentration of hepatic non-enzymatic antioxidant-reduced glutathione (GSH) has shown in figure 6. A significant decline was observed in the concentration

of GSH in diabetic control rats compared to the normal control rats. In contrast, GSH concentration was significantly enhanced after treatment with HA or metformin in the liver of diabetic rats.



**Figure 6.** Reduced Glutathione content (GSH) in liver

Values are presented as mean ± SD (n = 6). Group I: Normal control(N); Group II: Normal rats given 50 mg Hibiscus anthocyanin (HA) /kg body weight of rats (N+HA); Group III: Diabetic control (D); Group IV: Diabetic rats given 50 mg Hibiscus anthocyanin (HA)/kg body weight of rats (D+HA); V: Diabetic rats given 150 mg metformin/kg body weight of rats (D+M). 'a' indicates values significantly different from normal control groups. 'b' indicates values significantly different from diabetic groups. Significance accepted at p<0.05.

**Lipid peroxidation products in the liver:** The levels of lipid peroxidation products, Thiobarbituric acid-reactive substances (TBARS), hydroperoxides (HP), and conjugated dienes (CD) in the liver of normal and experimental animals were shown in table 3. A significant elevation was observed in the levels of

TBARS, HP, and CD in the liver of diabetic control rats as compared to normal control rats. Diabetic rats treated with HA or metformin showed a significant reduction in the levels of lipid peroxidation products compared to diabetic control groups (Table 3).

**Table 3:** Lipid peroxidation products in the liver

GROUPS	TBARS (mM/100 g tissue)	CD (mM/100 g tissue)	HP (mM/100 g tissue)
I	1.57 ± 0.149	27.8 ± 2.66	53.48 ± 5.12
II	1.44 ± 0.134	23.1 ± 2.22 <sup>a</sup>	41.50 ± 3.97 <sup>a</sup>
III	2.75 ± 0.260 <sup>a</sup>	45.0 ± 4.35 <sup>a</sup>	90.86 ± 8.7 <sup>a</sup>
IV	1.82 ± 0.175 <sup>b</sup>	31.6 ± 3.04 <sup>b</sup>	58.50 ± 5.61 <sup>b</sup>
V	1.87 ± 0.80 <sup>b</sup>	35.3 ± 3.41 <sup>b</sup>	63.36 ± 6.09 <sup>b</sup>

Values are expressed as mean ± SD (n = 6). Group I: Normal control(N); Group II: Normal rats given 50 mg Hibiscus anthocyanin (HA) /kg body weight of rats (N+HA); Group III: Diabetic control (D); Group IV: Diabetic rats given 50 mg Hibiscus anthocyanin (HA)/kg body weight of rats (D+HA); V: Diabetic rats given 150 mg metformin/kg body weight of rats (D+M). 'a' indicates values significantly different from normal control groups. 'b' indicates values significantly different from diabetic groups. Significance accepted at p<0.05

## DISCUSSION

Hyperglycemia triggers oxidative stress and reduces the antioxidant defense mechanism by generating advanced glycation end products. (AGEs). As oxidative stress perturbs the antioxidant defense system, it plays a critical role in diabetes complications [29]. In the current study, we identified that the anthocyanins present in the *Hibiscus rosa sinensis* flower petals could attenuate hyperglycemia-induced hepatic injury by mitigating oxidative stress. The reduction in body weight associated with diabetes is caused by dehydration, carbohydrate loss, and the excessive breakdown of fats and proteins in

tissues [30]. The results of our study corroborate this; body weights were significantly diminished in STZ-induced diabetic rats. The oral administration of HA or metformin to diabetic rats for 30 days significantly improved the body weight, which indicated the efficacy of Hibiscus anthocyanins in maintaining better glycemic control in diabetic rats.

Streptozotocin is one of the diabetogenic substances used to induce diabetes mellitus in experimental animals. The intraperitoneal injection of STZ partially damages the insulin-secreting pancreatic beta cells by breaking the DNA strand, resulting in decreased insulin biosynthesis and secretion [31-32]. The impairment in the synthesis of

insulin leads to persistent hyperglycemia [33-34]. In the present study, the blood glucose level was significantly elevated in diabetic control rats. However, treatment with HA or metformin significantly reduced the blood glucose level in diabetic rats, which suggests that *Hibiscus* anthocyanins protect the pancreatic  $\beta$ -cells against hyperglycemia-induced oxidative stress and could also preserve their functionality and insulin release. This result agrees with the previous studies that showed the protective role of flavonoid-rich ethyl acetate fraction of *Hibiscus rosa sinensis* petals in insulin secretion in  $\beta$ -cells under high glucose conditions in RIN-m5F cells [35].

Glycosylated hemoglobin (HbA1c) is a useful marker to assess the risk of diabetes mellitus. HbA1c is formed from the non-enzymatic and irreversible covalent bonding of glucose with Hb in circulation. The increase in HbA1c in diabetic patients is directly proportional to fasting blood glucose [36]. Similar to previous reports, we found that diabetic control rats had a significantly higher level of HbA1c. In contrast, rats that were treated with HA or metformin showed significant declines in HbA1c. The reduction in the level of HbA1c in HA-treated diabetic rats indicated the anti-hyperglycemic effect of *Hibiscus* anthocyanins by ameliorating glycemic control.

Hepatic marker enzymes (Alanine aminotransferase and Aspartate aminotransferase) elevated in the bloodstream indicate hepatocellular damage as these enzymes appear to have leaked from the liver into the bloodstream. [37]. Consistent with the previous reports, our results showed the activities of AST and ALT were significantly higher in diabetic control rats. However, the oral administration of HA or metformin significantly reduced the activities of AST and ALT in diabetic rats.

The activities of toxicity markers were not altered in normal rats administered with HA, indicating the non-toxic nature of HA in normal conditions. These findings revealed the hepatoprotective nature of *Hibiscus* anthocyanins extract. Earlier studies have reported that anthocyanin-rich black rice extract protects against alcohol-induced liver damage in rats [38].

Hyperlipidemia is one of the major risk factors for cardiovascular disease in type 2 diabetes. The characteristic features of diabetic dyslipidemia include elevated plasma concentrations of triglycerides and apo B-containing lipoproteins, low HDL cholesterol, and increased concentrations of small, dense LDL-cholesterol particles [39]. Consistent with the previous reports, in the present study, diabetic rats exhibited a significant elevation of TC, TG, and LDL-C while decreasing HDL-C. *Hibiscus* anthocyanins or metformin administration lowered TC, TG, and LDL-C levels with an elevation of HDL-C level. A decline in serum lipid profiles observed in *Hibiscus* anthocyanin administered diabetic rats suggests that its potential to regulate hyperlipidemia in the diabetic condition is mediated by the elevation of insulin level.

The increased production of ROS in hyperglycemia causes lipid peroxidation and tissue damage. The essential enzymatic antioxidants are superoxide dismutase (SOD), catalase (CAT), glutathione peroxidase (GPx), and glutathione reductase (GRd). Reduced glutathione (GSH) is a non-enzymatic antioxidant employed in free radical defense systems to remove radicals and protect biological sites [40]. SOD reduces superoxide radicals to hydrogen peroxide ( $H_2O_2$ ), and catalase reduces hydrogen peroxide to water and protects tissues from reactive hydroxyl radicals [41]. The activities of the

enzymatic and non-enzymatic antioxidant systems are depleted during oxidative stress [42]. In the current study, there was a decline in the activities of antioxidants enzymes SOD, CAT, GPx and, GRd in the liver of diabetic control rats. Treatment with HA and Metformin in diabetic rats enhanced antioxidant enzymes SOD, CAT, GPx and, GRd in the liver of diabetic rats. These results suggest that Hibiscus anthocyanins extract could improve the activities of enzymatic antioxidants, reduce free radicals, and alleviate liver damage caused by oxidative stress in diabetic rats. Our results are consistent with other studies showing that an anthocyanin-rich ethanolic extract of *Vaccinium Arctostaphylos* fruit increases antioxidant markers in alloxan-induced diabetic rats. [43].

Glutathione (GSH) is a tripeptide ( $\gamma$  - glutamyl cysteinyl glycine) and a non-enzymatic antioxidant molecule. It is critical for cellular protection, such as detoxification of ROS, conjugation, excretion of toxic molecules, and controlling the release of inflammatory cytokines [44]. In previous studies, GSH concentration was found to decline in diabetic rats [45]. In the present study, supplementation of HA and Metformin significantly increased GSH levels in diabetic rats. We found that Hibiscus anthocyanins extract protected the liver from oxidative damage by stimulating GSH synthesis.

Oxidative processes, glucose homeostasis, and detoxification of major metabolites produced by excessive reactive oxygen species are all vital functions of the liver [46]. Lipid peroxidation is an important biomarker of free radical-mediated oxidative stress. During this process, free radicals interact with polyunsaturated fatty acids (PUFAs), leading to the formation of malondialdehyde (MDA) and 4-hydroxynonenal, which cause adverse effects

such as cell necrosis and inflammation [47]. Increased lipid peroxidation induces disturbance of membrane organization, functional loss, modification of the protein, and DNA bases [48]. Diabetic rats have been shown to have elevated levels of lipid peroxidative markers (TBARS, HP, and CD) in the liver [49]. TBARS, HP, and CD were significantly elevated in the livers of diabetic control rats in the present study. Metformin and HA supplementation reduced TBARS, HP, and CD in the liver of diabetic rats. Hibiscus anthocyanins extract shows hepatoprotective properties against STZ induced hepatic injury by suppressing lipid peroxidation and restoring endogenous antioxidants. Results of the current study are consistent with previous studies showing that anthocyanin-rich mulberry extract inhibits oxidative stress induced by hyperglycemia by regulating the AMPK/ACC/mTOR pathway [50].

## CONCLUSION

In conclusion, the present study showed that Hibiscus anthocyanins (50mg/kg body weight) extract might provide effective protection against oxidative stress damage in the liver of STZ induced diabetic rats. Hibiscus anthocyanins may reduce lipid peroxidation and free radical levels in hepatic tissues as well as increase enzymatic and non-enzymatic antioxidant defense. Results from this study suggest that anthocyanin fraction of *Hibiscus rosa sinensis* flower petals may be effective against hepatic complications associated with DM. This study confirmed that supplementation of anthocyanins present in the *Hibiscus rosa sinensis* flower petals could significantly modulate the complications associated with hyperglycemia by modulating oxidative stress and

regulating antioxidant enzymes and afford protection against hepatic damage.

**List of abbreviations:** CAT: Catalase, CD: Conjugated dienes, DM: Diabetes Mellitus, GPx: Glutathione Peroxidase, GRd: Glutathione Reductase, GSH: Reduced Glutathione, HA: *Hibiscus rosa sinensis* flower anthocyanin, HbA1c: Glycosylated Hemoglobin, HDL-C: High-density Lipoprotein cholesterol, HP: Hydroperoxides, LDL-C: Low-density Lipoprotein cholesterol, ROS: Reactive oxygen species, SGOT: Serum Glutamate Oxaloacetate Transaminase, SGPT: Serum Glutamate Pyruvate Transaminase, SOD: Superoxide dismutase, STZ: Streptozotocin, TBARS: Thiobarbituric acid reactive substances

**Authors' contribution:** The original idea was conceived by V S Kalpana, Jincy Mary, and S Mini. This was discussed with N P Soumya and Sukanta Mondal.

## REFERENCES

- Ozougwu JC, Obimba KC, Belonwu CD, Unakalamba CB. The pathogenesis and pathophysiology of type 1 and type 2 diabetes mellitus. *Journal of physiology and pathophysiology* 2013, 4(4):46-57.  
<https://doi.org/10.5897/JPAP2013.0001>
- Valko M, Leibfritz D, Moncol J, Cronin MT, Mazur M, Telser J. Free radicals and antioxidants in normal physiological functions and human disease. *The international journal of biochemistry and cell biology* 2007, 39(1):44-84.  
[DOI: https://doi.org/10.1016/j.biocel.2006.07.001](https://doi.org/10.1016/j.biocel.2006.07.001)
- Yaribeygi H, Mohammadi MT, Sahebkar A. Crocin potentiates antioxidant defense system and improves oxidative damage in liver tissue in diabetic rats. *Biomedicine and Pharmacotherapy* 2018, 98:333-337.  
[DOI: https://doi.org/10.1016/j.biopha.2017.12.077](https://doi.org/10.1016/j.biopha.2017.12.077)
- Cichoż-Lach H, Michalak A. Oxidative stress as a crucial factor in liver diseases. *World journal of gastroenterology: WJG* 2014, 20(25):8082.  
[DOI: https://doi.org/10.3748/wjg.v20.i25.8082](https://doi.org/10.3748/wjg.v20.i25.8082)
- Cui H, Kong Y, Zhang H. Oxidative stress, mitochondrial dysfunction, and aging. *Journal of signal transduction* 2012. [DOI: https://doi.org/10.1155/2012/646354](https://doi.org/10.1155/2012/646354)
- Ugochukwu NH, Babady NE. Antioxidant effects of *Gongronema latifolium* in hepatocytes of rat models of non-insulin dependent diabetes mellitus *Fitoterapia* 2002, 73(7-8):612-618.  
[DOI: https://doi.org/10.1016/s0367-326x\(02\)00218-6](https://doi.org/10.1016/s0367-326x(02)00218-6)
- Abbas ZK, Saggi S, Sakeran MI, Zidan N, Rehman H, Ansari AA. Phytochemical, antioxidant and mineral composition of hydroalcoholic extract of chicory (*Cichorium intybus* L.) leaves. *Saudi journal of biological sciences* 2015, 22(3):322-326.  
[DOI: https://doi.org/10.1016/j.sjbs.2014.11.015](https://doi.org/10.1016/j.sjbs.2014.11.015)

The main focus and ideas of the paper were finally agreed upon by all authors. The experiments were conducted and analyzed by V S Kalpana and Jincy Mary. S Mini conceptualized the main ideas behind the experiments. The main text of the paper was written by V S Kalpana and S Mini. The manuscript was revised and edited by S Mini and N P Soumya, with Sukanta Mondal contributing to the editing and writing parts. All authors contributed to the writing and editing of the final draft.

**Conflicts of Interest:** We wish to declare that there are no conflicts of interest associated with this study.

**Acknowledgements:** The financial assistance from Kerala State Council for Science, Technology, and Environment (KSCSTE) Research fellowship (No 001/FSHP- MAIN /2015), Thiruvananthapuram, Kerala, and the facilities provided by the University of Kerala are greatly acknowledged.

8. Jadhav VM, Thorat RM, Kadam VJ, Sathe NS. Traditional medicinal uses of *Hibiscus rosa-sinensis*. *J Pharm Res* 2009, 2(8):1220-1222.
9. Pillai SS, Mini S. *Hibiscus rosa sinensis* Linn. petals modulates glycogen metabolism and glucose homeostasis signalling pathway in streptozotocin-induced experimental diabetes. *Plant foods for human nutrition* 2016, 71(1):42-48.  
DOI: <https://doi.org/10.1007/s11130-015-0521-6>
10. Bunea A, Rugină D, Sconța Z, Pop RM, Pinteș A, Socaci C, Tăbăran F, Grootaert C, Struijs K, VanCamp J. Anthocyanin determination in blueberry extracts from various cultivars and their antiproliferative and apoptotic properties in B16-F10 metastatic murine melanoma cells. *Phytochemistry* 2013, 95:436-444.  
DOI: <https://doi.org/10.1016/j.phytochem.2013.06.018>
11. Gowd V, Bao T, Chen W. Antioxidant potential and phenolic profile of blackberry anthocyanin extract followed by human gut microbiota fermentation. *Food research international* 2019, 120:523-533.  
DOI: <https://doi.org/10.1016/j.foodres.2018.11.001>
12. Fallah AA, Sarmast E, Jafari T. Effect of dietary anthocyanins on biomarkers of oxidative stress and antioxidative capacity: A systematic review and meta-analysis of randomized controlled trials. *Journal of Functional Foods* 2020, 68:103912.  
<https://doi.org/10.1016/j.jff.2020.103912>
13. Parthasarathi S, Ezhilarasi PN, Jena BS, Anandharamakrishnan C. A comparative study on conventional and microwave-assisted extraction for microencapsulation of *Garcinia* fruit extract. *Food and Bioproducts Processing* 2013, (2):103-110.  
DOI: <https://doi.org/10.1016/j.fbp.2012.10.004>
14. Wedick NM, Pan A, Cassidy A, Rimm EB, Sampson L, Rosner B, Willett W, Hu FB, Sun Q, van Dam RM. Dietary flavonoid intakes and risk of type 2 diabetes in US men and women. *The American journal of clinical nutrition* 2012, (4):925-933.  
DOI: <https://doi.org/10.3945/ajcn.111.028894>
15. Longo L, Scardino A, Vasapollo G. Identification and quantification of anthocyanins in the berries of *Pistacia lentiscus* L., *Phillyrea latifolia* L. and *Rubia peregrina* L. *Innovative Food Science and Emerging Technologies* 2007, 8(3):360-364.  
DOI: <https://doi.org/10.1016/j.ifset.2007.03.010>
16. Rapisarda P, Fanella F, Maccarone E. Reliability of analytical methods for determining anthocyanins in blood orange juices. *Journal of Agricultural and Food Chemistry* 2000, 48(6):2249-2252.  
DOI: <https://doi.org/10.1021/jf991157h>
17. Pazmiño-Durán EA, Giusti MM, Wrolstad RE, Glória MB. Anthocyanins from *Oxalis triangularis* as potential food colorants. *Food Chemistry* 2001, 75(2):211-216.  
DOI: [https://doi.org/10.1016/S0308-8146\(01\)00201-1](https://doi.org/10.1016/S0308-8146(01)00201-1)
18. Ramesh B, Pugalendi KV. Antihyperglycemic effect of umbelliferone in streptozotocin-diabetic rats. *Journal of medicinal food* 2006, (4):562-566.  
DOI: <https://doi.org/10.1089/jmf.2006.9.562>
19. Huggett AS, Nixoh DA. Use of glucose oxidase, peroxidase, and O-dianisidine in determination of blood and urinary glucose. *Lancet* 1957, 273:368-370.  
DOI: [https://doi.org/10.1016/s0140-6736\(57\)92595-3](https://doi.org/10.1016/s0140-6736(57)92595-3)
20. Reitman S, Frankel S. A colorimetric method for the determination of serum glutamic oxalacetic and glutamic pyruvic transaminases. *American journal of clinical pathology*. 1957, (1):56-63.  
DOI: <https://doi.org/10.1093/ajcp/28.1.56>
21. Maehly AC, Chance B. *Methods of biochemical analysis*. by Glick D., Interscience, New York. 1954:454.  
DOI: <https://doi.org/10.1002/9780470110171.ch14>
22. Kakkar P, Das B, Viswanathan PN. A modified spectrophotometric assay of superoxide dismutase.
23. Agergaard N, Jensen PT. Procedure for blood glutathione peroxidase determination in cattle and swine. *Acta Veterinaria Scandinavica*. 1982, (4):515-527. DOI: <https://doi.org/10.1186/BF03546770>
24. Hovatta I, Tennant RS, Helton R, Marr RA, Singer O, Redwine JM, Ellison JA, Schadt EE, Verma IM, Lockhart DJ, Barlow C. Glyoxalase 1 and glutathione reductase 1 regulate anxiety in mice. *Nature* 2005, (7068):662-666.  
DOI: <https://doi.org/10.1038/nature04250>
25. Patterson JW. Determination of glutathione. *Methods Biochem Anal* 1955, 2:259-278.  
DOI: <https://doi.org/10.1002/9780470110188.ch9>
26. Okhawa H, Ohishi N, Yagi K. Reaction of linoleic acid hydroperoxides with thiobarbituric acids. *Anal Biochem* 1979, 95(2):351-354.  
DOI: [https://doi.org/10.1016/0003-2697\(79\)90738-3](https://doi.org/10.1016/0003-2697(79)90738-3)



27. Buege JA, Aust SD. Microsomal lipid peroxidation. In Methods in enzymology 1978, 52:302-310. Academic press.  
DOI: [https://doi.org/10.1016/s0076-6879\(78\)52032-6](https://doi.org/10.1016/s0076-6879(78)52032-6)
28. Lowry OH, Rosebrough NJ, Farr AL, Randall RJ. Protein measurement with the Folin phenol reagent. Journal of biological chemistry 1951, 193:265-75.  
[https://doi.org/10.1016/S0021-9258\(19\)52451-6](https://doi.org/10.1016/S0021-9258(19)52451-6)
29. Muruganathan U, Srinivasan S. Beneficial effect of carvone, a dietary monoterpene ameliorates hyperglycemia by regulating the key enzymes activities of carbohydrate metabolism in streptozotocin-induced diabetic rats. Biomedicine and Pharmacotherapy 2016, 84:1558-1567.  
DOI: <https://doi.org/10.1016/j.biopha.2016.11.025>
30. Srinivasan S, Muruganathan U. Antidiabetic efficacy of citronellol, a citrus monoterpene by ameliorating the hepatic key enzymes of carbohydrate metabolism in streptozotocin-induced diabetic rats. Chemicobiological interactions 2016, 250:38-46.  
DOI: <https://doi.org/10.1016/j.cbi.2016.02.020>
31. Kim MJ, Ryu GR, Chung JS, Sim SS, Min DS, Rhie DJ, Yoon SH, Hahn SJ, Kim MS, Jo YH. Protective Effects of Epicatechin against the Toxic Effects of Streptozotocin on Rat Pancreatic Islets: in vivo and in vitro. Korean Journal of Physiology and Pharmacology 2002, 6:67-70.  
DOI: <https://doi.org/10.1097/00006676-200304000-00014>
32. Murali R, Srinivasan S, Ashokkumar N. Antihyperglycemic effect of fraxetin on hepatic key enzymes of carbohydrate metabolism in streptozotocin-induced diabetic rats. Biochimie 2013, 95(10):1848-1854.  
DOI: <https://doi.org/10.1016/j.biochi.2013.06.013>
33. Sundaram R, Naresh R, Shanthi P, Sachdanandam P. Efficacy of 20-OH-ecdysone on hepatic key enzymes of carbohydrate metabolism in streptozotocin induced diabetic rats. Phytomedicine 2012,19(8-9):725-729.  
DOI: <https://doi.org/10.1016/j.phymed.2012.02.019>
34. Saini V. Molecular mechanisms of insulin resistance in type 2 diabetes mellitus. World journal of diabetes 2010, 1(3):68.  
DOI: <https://doi.org/10.4239/wjd.v1.i3.68>
35. Pillai, Sneha S., and S. Mini. Attenuation of high glucose induced apoptotic and inflammatory signaling pathways in RIN-m5F pancreatic  $\beta$  cell lines by Hibiscus rosa sinensis L. petals and its phytoconstituents. Journal of ethnopharmacology 2018, 8-17.  
DOI: <https://doi.org/10.1016/j.jep.2018.08.022>
36. Edelman D, Olsen MK, Dudley TK, Harris AC, Oddone EZ. Utility of hemoglobin A1c in predicting diabetes risk. Journal of general internal medicine 2004, 19(12):1175-1180.  
DOI: <https://doi.org/10.1111/j.1525-1497.2004.40178.x>
37. Ashokkumar N, Pari L. Effect of N-benzoyl-D-phenylalanine and metformin on carbohydrate metabolic enzymes in neonatal streptozotocin diabetic rats. Clinica chimica acta 2005, 351(1-2):105-113.  
DOI: <https://doi.org/10.1016/j.cccn.2004.08.011>
38. Hou Z, Qin P, Ren G. Effect of anthocyanin-rich extract from black rice (*Oryza sativa* L. Japonica) on chronically alcohol-induced liver damage in rats. Journal of agricultural and food chemistry 2010, 58(5):3191-3196.  
DOI: <https://doi.org/10.1021/jf904407x>
39. Mooradian AD. Dyslipidemia in type 2 diabetes mellitus. Nature Reviews Endocrinology 2009, 5(3):150-159.  
DOI: <https://doi.org/10.1038/ncpendmet1066>
40. Ighodaro OM, Akinloye OA. First line defence antioxidants-superoxide dismutase (SOD), catalase (CAT) and glutathione peroxidase (GPX): Their fundamental role in the entire antioxidant defence grid. Alexandria journal of medicine 2018, 54(4):287-293.  
<https://doi.org/10.1016/j.ajme.2017.09.001>
41. Sözmen EY, Sözmen B, Delen Y, Onat T. Catalase/superoxide dismutase (SOD) and catalase/paraoxonase (PON) ratios may implicate poor glycemic control. Archives of medical research 2001, 32(4):283-287.  
DOI: [https://doi.org/10.1016/s0188-4409\(01\)00285-5](https://doi.org/10.1016/s0188-4409(01)00285-5)
42. Maritim AC, Sanders A, Watkins Iii JB. Diabetes, oxidative stress, and antioxidants: a review. Journal of biochemical and molecular toxicology 2003,17(1):24-38.  
DOI: <https://doi.org/10.1002/jbt.10058>
43. Feshani AM, Kouhsari SM, Mohammadi S. Vaccinium arctostaphylos, a common herbal medicine in Iran: Molecular and biochemical study of its antidiabetic effects on alloxan-diabetic Wistar rats. Journal of ethnopharmacology 2011, 133(1):67-74.

- DOI: <https://doi.org/10.1016/j.jep.2010.09.002>
44. Brown LA, Harris FL, Ping XD, Gauthier TW. Chronic ethanol ingestion and the risk of acute lung injury: a role for glutathione availability? *Alcohol* 2004, 33(3):191-197.  
DOI: <https://doi.org/10.1016/j.alcohol.2004.08.002>
45. Sayed AA. Ferulsinic acid modulates SOD, GSH, and antioxidant enzymes in diabetic kidney. *Evidence-Based Complementary and Alternative Medicine* 2012.  
DOI: <https://doi.org/10.1155/2012/580104>
46. Kapoor R, Kakkar P. Naringenin accords hepatoprotection from streptozotocin induced diabetes in vivo by modulating mitochondrial dysfunction and apoptotic signaling cascade. *Toxicology reports* 2014, 1:569-581.  
DOI: <https://doi.org/10.1016/j.toxrep.2014.08.002>
47. Ayala A, Muñoz MF, Argüelles S. Lipid peroxidation: production, metabolism, and signaling mechanisms of malondialdehyde and 4-hydroxy-2-nonenal. *Oxidative medicine and cellular longevity* 2014.  
DOI: <https://doi.org/10.1155/2014/360438>
48. Niki E. Lipid peroxidation: physiological levels and dual biological effects. *Free Radical Biology and Medicine* 2009, (5):469-484. DOI: <https://doi.org/10.1016/j.freeradbiomed.2009.05.032>
49. Roy S, Sehgal R, Padhy BM, Kumar VL. Antioxidant and protective effect of latex of *Calotropis procera* against alloxan-induced diabetes in rats. *Journal of Ethnopharmacology* 2005, 102(3):470-473.  
DOI: <https://doi.org/10.1016/j.jep.2005.06.026>
50. Yan F, Zheng X. Anthocyanin-rich mulberry fruit improves insulin resistance and protects hepatocytes against oxidative stress during hyperglycemia by regulating AMPK/ACC/mTOR pathway. *Journal of Functional Foods* 2017, 30:270-281.  
<https://doi.org/10.1016/j.jff.2017.01.027>