



## A review of ethnomedicinal remedies for Peptic Ulcers

Great O. Adebodun<sup>1\*</sup>, Dorcas O. Odunaike<sup>2</sup>, Laide O. Olajide<sup>2</sup>, Abayomi S. Adebodun<sup>3</sup>, Abolanle A.A. Kayode<sup>2\*</sup>

<sup>1</sup>Department of Physiology, School of Basic Medical Sciences, Babcock University, Ilishan-Remo, Ogun State, Nigeria;

<sup>2</sup>Department of Biochemistry, School of Basic Medical Sciences, Babcock University, Ilishan-Remo, Ogun State, Nigeria;

<sup>3</sup>Department of Pharmacognosy, Faculty of Pharmacy, University of Ibadan, Ibadan, Oyo State, Nigeria

**\*Corresponding Authors:** Great O. Adebodun, Department of Physiology, School of Basic Medical Sciences, Babcock University, Ilishan-Remo, Ogun State, Nigeria; Abolanle A.A. Kayode, Department of Biochemistry, School of Basic Medical Sciences, Babcock University, Ilishan-Remo, Ogun State, Nigeria.

**Submission Date:** October 18<sup>th</sup>, 2023; **Acceptance Date:** November 7<sup>th</sup>, 2023; **Publication Date:** November 9<sup>th</sup>, 2023

**Please cite this article as:** Adebodun G. O., Odunaike D. O., Olajide L. O., Adebodun A. S., Kayode A. A. A. Review of some ethnomedicinal remedies for Peptic Ulcer. *Functional Food Science* 2023; 3(11): 258-274.

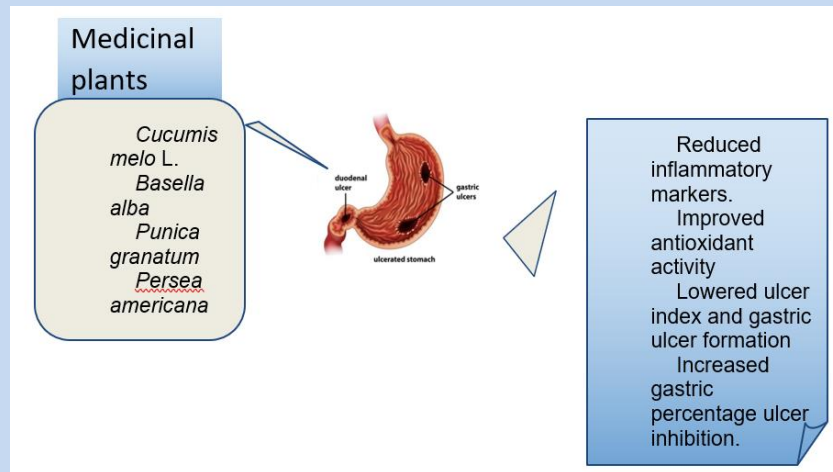
DOI: <https://www.doi.org/10.31989/ffs.v3i11.1246>

### ABSTRACT

Peptic ulcers are the deep damage of the stomach or duodenal mucosa, extending past the muscularis mucosa. This occurs when the mucosal defences including prostaglandins, mucus, and sufficient blood flow are altered. *Helicobacter pylori* (*H. pylori*) and the use of non-steroidal anti-inflammatory drugs (NSAIDs) are the two primary causatives linked with the etiology of peptic ulcer disease. Other causative agents include smoking, ischemia, hydrochloric acid, and alcohol. Drugs used in the treatment include histamine-2 receptor antagonists, and proton pump inhibitors, which have been discovered to possess adverse effects. Medicinal plants, however, are beneficial and effective in the prevention, management, and treatment of various ailments. Therefore, this review highlights common medicinal plants and their mechanisms of action in preventing or treating peptic ulcers. The websites ResearchGate, ScienceDirect, Google Scholar and PubMed were searched for relevant articles published between 2019-2023 using the keywords “medicinal plants and peptic ulcer” and “medicinal plants and gastric ulcer”. According to the research articles, some of the mechanisms of action include lowered gastric index, inflammation, and gastric lesions, increased gastric pH, protective index, and antioxidant levels. However, more studies should be carried out to determine the active compounds in these plants.

Human clinical trials are also needed to validate the safety and efficacy of these medicinal plants since most of the studies enumerated in this review are animal-based studies.

**Keywords:** Peptic ulcer, medicinal plants, *Helicobacter pylori*



©FFC 2023. This is an Open Access article distributed under the terms of the Creative Commons Attribution 4.0 License (<http://creativecommons.org/licenses/by/4.0>)

## INTRODUCTION

The stomach produces enzymes and acids that break down food and are resistant to a wide range of harmful substances such as refluxed bile salts, hydrochloric acid, alcohol, and other irritants. Several physiological defense responses are present in the stomach, not only to prevent damage but also to enhance prompt healing of the mucosa and to allow the mucosa to maintain high resistance to injury. A stomach mucosal lesion in the stomach, such as a gastric erosion or ulcer may form when these defense systems are overpowered by irritants [1]. The mucosal barrier is altered by aggressive factors, which leads to damage to the stomach's epithelial cells and ultimately results in peptic ulcer disease (PUD). Peptic ulcer disease (PUD) is characterized by damage to the duodenum or mucosa of the stomach caused by gastric secretions [2-3]. Current research indicates that many variables, such as overproduction of stomach acid, *Helicobacter pylori* infection, pepsin, alcohol consumption, smoking, diet, and genetic factors,

can contribute to the onset of PUD and serve as possible risk factors for its development [1].

According to epidemiological studies, PUD and *H. pylori* infection have a very significant link. Over half of the global population has a chronic *H. pylori* infection in the gastroduodenum, but only 5–10% of this population eventually develop ulcers. The pattern of histological alterations, interaction of *H. pylori* with the stomach mucosa, homeostatic changes in acid secretion and gastric hormones, immunopathogenesis, ulcerogenic strains, and genetic factors influence peptic ulcer manifestation [4]. Other etiologies of peptic ulcer disease are histamine, ischemia, steroid medication, radiation, viruses, eosinophilic infiltration, gastric bypass surgery, and pharmaceuticals such as chemotherapeutic drugs, and radiotherapy [5]. Symptoms of PUD include heart burn, bloating, nausea, and the major ulcer symptom is burning stomach pain. Diagnosis includes blood, urea breath, stool tests, gastrointestinal endoscopy. Treatments for PUD include proton pump inhibitors (PPI),

H<sub>2</sub> receptor antagonists and successive H. pylori treatment. These treatments can possess adverse effects such as diarrhea, headache, constipation, abdominal discomfort.

**Pathophysiology of Peptic Ulcer Disease:** A disruption in the equilibrium between defensive and aggressive forces results in mucosal damage [6-7]. Hence, peptic ulcer is described as a distortion extending through the muscularis mucosa in the stomach or duodenal mucosa and submucosa. In response to cholinergic stimulation or irritation of the epithelial lining, epithelial cells of the stomach and duodenum release mucus. Mucus and bicarbonate produced by the foveolar cells combine to form a gel layer which is impermeable to pepsin and acid. This layer is crucial because it stops the stomach from digesting itself. Additional defenses prevent pepsin and acid from penetrating the epithelium in the event of injury. For instance, an increase in blood flow eliminates acid that diffuses through the damaged mucosa and adequately supplies epithelial cells with bicarbonate in

the gel layer. The basolateral region of the cell membrane of epithelial cells has ion channels which also aid in maintaining intracellular pH by reducing excess hydrogen ions [1].

NSAIDs suppress cyclooxygenase-1 (COX-1) expression involved in prostaglandin production and are linked with reduced bicarbonate and mucus secretion, flow of blood to the gastric mucosa, and inhibited cell proliferation. NSAIDs also initiate damage to the mucosal lining (Fig. 1) [5].

*Helicobacter pylori*, one of the common etiologies of peptic ulcer causes degeneration and injury of epithelial cells, inflammation of neutrophils, lymphocytes, and macrophages [8]. *H. pylori* infection is mediated by cytokines that suppress parietal cell secretion and is characterized by elevated gastric juice secretion and decreased somatostatin level. This increases histamine production, and eventually gastric acid secretion from the parietal cells [5].

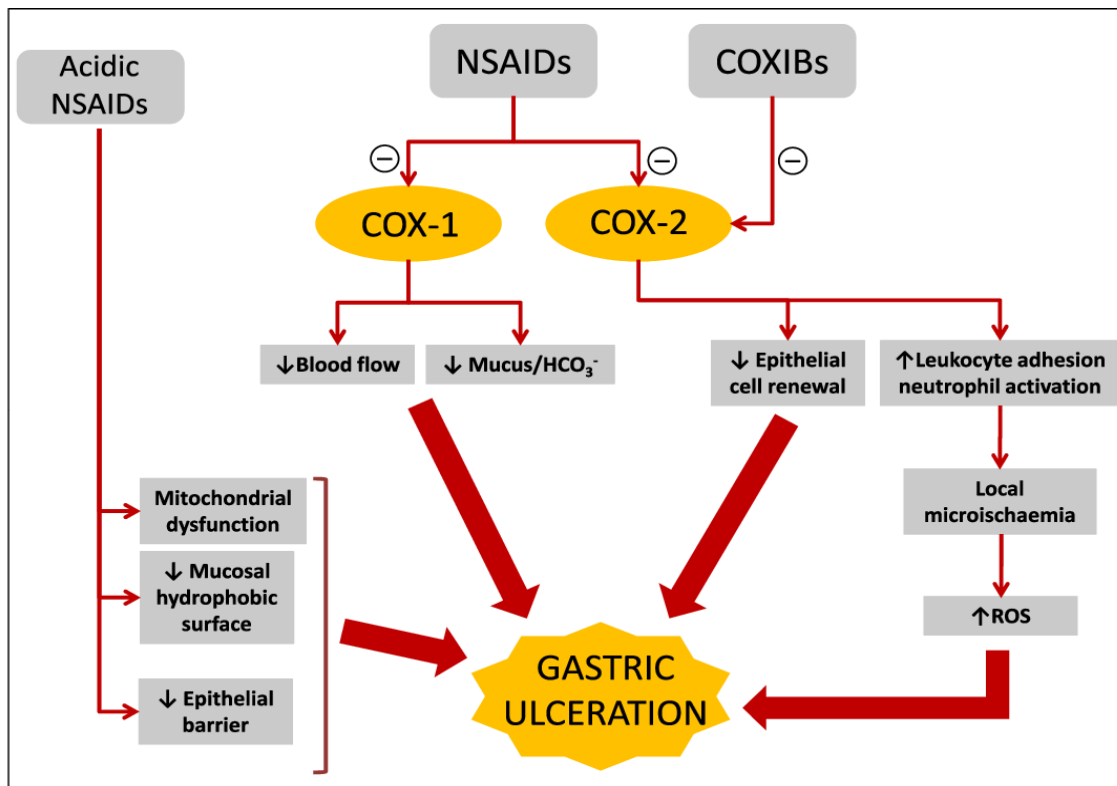


Fig 1: Pathophysiology of Peptic ulcer by NSAIDs [9].

## METHODOLOGY

Different databases such as PubMed, Scopus, Web of Science, ScienceDirect, ResearchGate, Google Scholar were used in this review article with the following keywords: “medicinal plants”, “herbal treatment”, “gastric ulcer” and ‘peptic ulcer’. The references for this review were selected based on these criteria: articles

published between 2019-2023, full-text original articles, and relevance to the review topic.

**Herbal Remedies for Peptic Ulcer Disease:** Studies have proven medicinal plants or their bioactive constituents to be beneficial in treating peptic ulcers and their efficacy is better or similar to the conventional drugs with fewer side effects [10].

**Table 1:** A summary of the modes of action of some medicinal plants with gastroprotective and anti-ulcer properties

S/N	Medicinal Plants	Description	Outcome	References
1	Cucumis melo L.	-25%, 50%, 75%, 100% CUM aqueous extract at 1 ml/kg were administered on ibuprofen-induced gastric ulcer in rats for 21 days. - 200 and 600 mg/kg ethanol extract of CUM were administered in ethanol-induced gastric ulcer in rats	- Gastric acidity, ulcer score, MDA, TNF- $\alpha$ , H <sup>+</sup> /K <sup>+</sup> ATPase were significantly reduced while PGE <sub>2</sub> , % inhibition, antioxidants level was significantly increased. -Both doses reduced the number of lesions and increased percentage protection.	12-13
2	Lawsonia inermis L. leaves	200 g/kg nano Lawsonia inermis L. and Lawsonia inermis L. leaves were administered to aspirin-induced peptic ulcer in Sprague-dawley rats for 8 weeks	Levels of total cholesterol, MDA, AST, ALP, creatinine, albumin, total protein were significantly reduced with an increase in pH and HDL level. Regressed lesions in the stomach were observed.	18
3	Dissotis rotundifolia	Ethanol-induced ulcer rats were pre-treated with 100, 300 and 500 mg/kg D. rotundifolia for 14 days	MDA level, ulcer index and gastric ulcer formation were significantly lowered while GSH, CAT and SOD levels were significantly increased in all pre-treated rats. The 300 mg/kg dose had the highest gastric percentage protection.	20
4	Punica granatum	-In aspirin-induced ulcer rabbits, 250 and 500 mg/kg P. granatum peel powder was administered for 21 days. - The effect of 250 and 500 mg/kg P. granatum peels was compared with omeprazole, a standard drug in H. Pylori-induced gastric ulcer in rats	-Ulcer index and gastric acid volume were reduced with increased pH and percentage gastric protection. - The 500 mg/kg had an ulcer inhibition percentage of 84.6 compared with omeprazole of 24.5%. A dose dependent decrease in the ulcer area was observed with the 500 mg/kg group having the largest reduction (125.5mm <sup>2</sup> ) compared with omeprazole (615.25mm <sup>2</sup> ).	32, 34
5	Persea americana Mill. (Lauraceae)	-Aqueous extract, water, and n-hexane fractions of Persea americana seed at 250 and 500 mg/kg were administered to ethanol, aspirin and stress-induced ulcer in rats. -Virgin avocado oil (1 mL/250 g body weight) was pre-administered to	- The 500 mg/kg aqueous extract and all the fractions showed significant reduction in ulcer index. However, n-hexane exhibited the highest ulcer healing potential. -The avocado oil ameliorated the ulcerations in both indomethacin and ethanol ulcer models. The ulcer index was significantly reduced.	37, 39

S/N	Medicinal Plants	Description	Outcome	References
		ethanol and indomethacin-induced ulcer in rats for 7 days.		
6	<i>Acanthus montanus</i> (Nees) T. Anderson	The anti-ulcer effect of crude extract and n-hexane, ethyl acetate, n-butanol, water fractions of <i>Acanthus montanus</i> at 200 and 400 mg/kg was evaluated in indomethacin-induced ulcer in mice for 7 days.	The aqueous fraction had the highest anti-ulcer activity. The crude extract, aqueous and n-hexane fractions had gastro-protective effect on the gastric mucosa.	43
7	<i>Torilis Leptophylla</i>	100, 200, 300 mg/kg of <i>Torilis Leptophylla</i> were administered in indomethacin-induced ulcer in rats for 3 days.	All the <i>Torilis leptophylla</i> extract treated groups had significant decrease in gastric juice volume, ulcer index, number of lesions and ulcer percentage with significant increase in pH.	46
8	<i>Nymphaea lotus</i> Linn and <i>Nymphaea Alba</i> Linn	The gastro-protective potential of the methanol extract of <i>N. lotus</i> leaves was evaluated in ethanol, indomethacin, and hypothermic stress-induced ulcer rats. - Ethanol extract of <i>Nymphaea alba</i> L. flower (200, 400 mg/kg) was administered in pylorus ligation and ethanol induced ulcer in rats	-Pre-treatment with the methanol extract had significantly decreased gastric ulcer indices and lesions in all gastric ulcer models. The epithelial mucosa was moderately disintegrated 200 mg/kg treated rats, minor hemorrhages were observed in 400 mg/kg treated rats with no gastric lesions in the 600 mg/kg treated rats. - The 400 and 200 mg/kg treated groups had significant reduction in the ulcer index when compared to the untreated groups.	48-49
9	<i>Morus alba</i> L.	The effect of <i>Morus alba</i> L. extract (500 mg/kg) and <i>Morus alba</i> L. (500 mg/kg) extract-loaded chitosan microsphere was investigated in ethanol-induced ulcer rats.	There was a significant reduction in the total acidity, gastric ulcer index, gastric volume, and gastric lesions while pH level was significantly increased.	51
10	<i>Magnolis Officinalis</i>	In pylorus ligation-induced gastric ulcer mice, 100 mg/kg water extract of <i>Magnolis officinalis</i> was administered for 28 days.	There was a significant decrease in IL-6, TNF- $\alpha$ levels, gastric juice secretion and ulcer index; increased pH of gastric juice and CB2 gene expression.	53
11	<i>Triticum aestivum</i> Linn	<i>Triticum aestivum</i> aqueous extract (50, 100, 200 mg/kg) was administered to acetic acid and indomethacin-induced ulcer rats for 2 weeks. -Gastroprotective activity of 200 and 400 mg/kg <i>Triticum aestivum</i> extract was investigated in ethanol-induced gastric ulcer in rats	There was significantly increased CAT and NO levels and reduced MDA level. -There was significant reduction in the ulcer index, MDA levels while TAC, CAT and GSH levels were significantly increased.	57-58
12	<i>Basella Alba</i> L.	The anti-ulcer effect of 100, 200 and 400 mg/kg ethanol extract of <i>Basella alba</i> was investigated in aspirin and pyloric ligation-induced ulcer in rats.	There was a significant reduction in gastric volume, ulcer index and acidity while gastric pH and percentage protection were significantly increased.	69

***Cucumis melo* L. (Cucurbitaceae):** *Curcumis melo* L. (CUM) also known as honeydew melon or melon has

steroids, cardiac glycosides, flavonoids, polyphenols, terpenoids and alkaloids that possess anti-inflammatory,

antioxidants, and anti-radical potentials [11]. Adebayo-Gege *et al.* [12] investigated the antiulcer properties of 25%, 50%, 75% and 100% CUM aqueous extract at 1 ml/kg dose for 21 days in ibuprofen-induced gastric ulcer in Wistar rats. Ulcer score and index, gastric acidity, MDA, TNF- $\alpha$ , H<sup>+</sup>/K<sup>+</sup>ATPase were significantly reduced with CUM administration when compared with the untreated ulcer group. PGE<sub>2</sub>, antioxidant potentials, percentage inhibition, CAT, SOD were significantly increased. Administration of CUM reduced submucosal bleeding and the severity of mucosal lining erosion. Molecular docking of *Cucumis melo* compounds was carried out against PGE<sub>2</sub> and folic acid had the highest affinity to PGE<sub>2</sub> receptor followed by codisterol and delta7-avenasterol. This showed that CUM exhibits its antiulcer activity via improved antioxidant capacity and prostaglandin synthesis. Bouaziz *et al.* [13] investigated the effect of 200 and 600 mg/kg ethanolic extract on *Cucumis melo* L in ethanol-induced gastric ulcer rats. Both doses attenuated the number and length of lesion, percentage ulceration was reduced, and gastric protection percentage was increased (56.56% and 93.79% respectively) in the 200 and 600 mg/kg CUM treated rats compared with the untreated rats, however, 600mg/kg dose had the maximum effect. Adebayo-Gege [14] investigated the antiulcer potentials of methanol extract of *Cucumis melo* seeds (50, 100, 200 mg/kg) on pyloric ligation-induced ulceration in Wistar rats. The rats were pretreated for 21 days before the pyloric ligation procedure. The extract significantly reduced the relative stomach weight, ulcer score, gastric acidity, MDA level while increasing the level of catalase.

***Lawsonia inermis* L. leaves (Lythraceae):** *Lawsonia inermis* L., also known as henna, is used for hand staining in traditional weddings and hair dyeing. However, it has been discovered to possess antitumor, antifungal,

antioxidant, antiproliferative, antiangiogenic, wound healing, antimalarial, hepatoprotective, antibacterial activities which could be due to coumarins, flavonoids, derivatives of gallic acid, triterpenoids, or steroids [15-17]. Mohammed *et al.* [18] investigated the effect of *nano Lawsonia inermis* L. and *Lawsonia inermis* L. leaves for a period of 8 weeks in male Sprague-Dawleys rats induced with peptic ulcer (500mg aspirin/kg body weight). The rats were fed with basal synthetic feed supplemented with 200 g/kg *Lawsonia inermis* L. and *nano Lawsonia inermis* L. leaves. Levels of gastric juice, total cholesterol, LDL, triglycerides, MDA, total antioxidant, creatinine, urea, AST, ALT, ALP, albumin, total protein, and globulin were significantly reduced while pH level, HDL significantly increased in both the *Lawsonia inermis* L. and *nano Lawsonia inermis* L. leaves treated rats compared to the untreated group. Histopathology of the stomach also revealed significantly regressed lesions and normal gastric layers.

***Dissotis rotundifolia* (Melastomataceae):** *Dissotis rotundifolia* (*D. rotundifolia*) also known as the 'pink lady' is a creeping herbal plant with antimicrobial, *in vivo* gastroprotective, and *in vitro* anti-radical properties [19-20]. Sprague Dawley rats were pretreated with 500, 300 and 100 mg/kg flavonoid-rich extract of *D. rotundifolia* for 2 weeks before inducing ulcer using ethanol. The ulcer index was significantly reduced in all pretreated rats with 300 mg/kg having the higher percentage gastric protection (95%). Reduced gastric ulcer formation was also observed in all the pretreated groups. Antioxidant activities in the gastric mucosa were investigated and the results showed that there was a significant reduction in MDA level while CAT, SOD and GSH levels were significantly increased in the pretreated groups [20]. Adinortey *et al.* [21] discovered that *D. rotundifolia* extract significantly reduced gastric juice secretion and

H<sup>+</sup>/K<sup>+</sup> ATPase enzyme activity in aspirin-induced gastric ulcer rats whereas gastric mucus content, pH, and mucin activity were significantly increased.

***Punica granatum* L. (Lythraceae):** *P. granatum*, also referred to as pomegranate is a plant that has various beneficial parts (peels, seed oils, seeds, roots, bark, leaves, flower) [22]. The seeds improve male fertility and are used to treat cancer, cardiovascular diseases, diabetes, and obesity [23-24]. The flowers are used to manage diabetes, obesity, heart diseases and treat bacteria [25-26]. The leaves have anti-inflammatory, anti-cancer, anti-cholinesterase, and anti-diabetic properties [27-28] and the peels possess antioxidant, anti-cancer, anti-inflammatory, and anti-proliferative properties [29-31]. In aspirin-induced ulcer rabbits, 500 and 250 mg/kg body weight of *P. granatum* peel powder was administered for 3 weeks. Ulcer index and gastric acid volume were reduced with increased pH and percentage gastric protection compared with the ulcer untreated group [32]. Piracha *et al.* [33] evaluated the effect of *P. granatum* seed and peel in diclofenac-induced ulcer rats. The rats were pretreated with the peel extract only (100 mg/kg), seed extract only (500 mg/kg), both peel (50 mg/kg) and seed (250 mg/kg) extract, pantoprazole (30mg/kg) and peel extract (50mg/kg), pantoprazole and seed extract (250 mg/kg), pantoprazole + peel extract (50 mg/kg) + seed extract (250 mg/kg) for 15 days and then orally administered 100mg/kg diclofenac on the 17<sup>th</sup> day. The total gastric juice volume and ulcer index were significantly reduced while pH of gastric juice was significantly increased in all the rats who were administered *P. granatum*. Muhiadin *et al.* [34] compared the effect of *Punica granatum* peels (250 mg/kg & 500mg/kg) with omeprazole (20 mg/kg) (a standard medication used in ulcer treatment) in *H. Pylori*-induced gastric ulcer in rats. The 500 mg/kg dose showed

an ulcer inhibition percentage of 84.6 compared with 24.5 of omeprazole. There was a dose-dependent reduction in the ulcer area of rats given the extract with the largest reduction (125.5mm<sup>2</sup>) in the 500mg/kg rats in comparison with the ulcer control group (815mm<sup>2</sup>) and the omeprazole-treated group (615.25mm<sup>2</sup>). There was a significant increase in the pH (6.3) of the 500 mg/kg *P. granatum*-treated group compared to the omeprazole group (5.5) and the untreated group (3.5) thereby suggesting that the high dose (500 mg/kg) was more effective. Ulcer scores were also significantly reduced after *P. granatum* treatment.

***Persea americana* Mill. (Lauraceae):** *Persea americana* is also known as Avocado tree. The seeds, fruits and leaves of *P. americana* possess antimicrobial, antiviral, anti-hypoglycemic, antihypertensive, anticonvulsant, anti-inflammatory, antioxidant properties [35-36]. Aqueous extract, and fractions (water, n-hexane) of *Persea americana* seed at 500 and 250 mg/kg were administered to ethanol, aspirin, and stress-induced ulcers in rats. The 500 mg/kg fractions and aqueous extract showed significant decrease in ulcer index in all the ulcer models. N-hexane however exhibited the highest ulcer healing potential [37]. The aqueous extract of *Persea americana* seeds (110, 220, 440 mg/kg) in aspirin-induced ulcer rats significantly decreased total carbohydrate and protein levels but increased the pepsin activity in the gastric juice. The level of MDA was significantly decreased while CAT, SOD, GSH levels were significantly elevated in comparison with the untreated group. The extract also had a protective effect on the gastric mucosa [38]. Virgin avocado oil (1mL/250 g body weight) was administered to rats for 7 days before ulcer induction with indomethacin (100 mg/kg) and ethanol (2 mL/kg) on the 8<sup>th</sup> day. Pre-treatment with avocado oil significantly

prevented ulcer formation with better protection against ulcer at a percentage inhibition of 39.2% compared to omeprazole with 17.5% inhibition. The ulcer index was also significantly reduced. The avocado oil ameliorated the ulcerations in both ethanol and indomethacin ulcer models [39]. Athaydes *et al* [40], investigated the effect of hydroalcoholic extract of *P.americana* seeds; its hexane and ethyl acetate fractions against *H. pylori* infection. Ethyl acetate fraction of *P.americana* seeds had a higher antioxidant activity with 91.80% inhibition for DPPH and 99.22% inhibition for ABTS at 6.25 µg/mL, 93.53% for hydrogen peroxide and 71.55% inhibition for hypochlorous acid at 25 µg/mL. The extracts were tested against two *H.pylori* strains; ATCC 43629 and ATCC 43504, ethyl acetate extract showed activity with MBC of 256 µg/mL and MIC of 128 µg/mL for ATCC 43629, MBC and MIC of 128 µg/mL for ATCC 43504. The ethyl acetate extract had a significant number of filamentous cells for both ATCC 43504 and ATCC 43629 with conversion of the bacterial folding to coccoid form in the ATCC 43629 strain. In indomethacin-induced gastric ulcer in rats, co-administration of fresh *P.americana* (1.5 and 3 mL) and *Actinidia deliciosa* (kiwi) (1.5 and 3 mL) juice for 3 weeks significantly reduced the ulcer index, MDA level and significantly elevated the pH, NO, GSH compared to untreated group. Kiwi juice at high doses 3 mL and 1.5 mL of avocado juice prevented ulcer formation [41].

***Acanthus montanus* (Nees) T. Anderson:** *Acanthus montanus* also referred to as alligator plant or bear's breech, is used in treating gastrointestinal and inflammatory diseases, body pains, cough [42]. The anti-ulcer effect of the crude extract and fractions (*n*-butanol, *n*-hexane, ethyl acetate, water) of *A. montanus* was evaluated in indomethacin-induced ulcer in mice. The mice received 200 and 400 mg/kg of the crude extract

and fractions for seven days after induction with indomethacin (30 mg/kg). The aqueous fraction had the highest antiulcer activity and ethyl acetate had the lowest activity with 400 mg/kg dose being the most effective in all the fractions. The crude extract, aqueous and *n*-hexane fractions had a protective effect on the gastric mucosa in the indomethacin-induced mice [43].

***Torilis leptophylla*:** Traditionally, *Torilis leptophylla* is used in the prevention and cure of gastrointestinal disorders. Alkaloids, glycosides, terpenoids present in this plant have been discovered to possess anti-inflammatory and antioxidant activities [44]. *Torilis leptophylla* also has antibacterial, anti-inflammatory, and neuroprotective potentials [44-45]. The anti-ulcer effect of *Torilis leptophylla* (100, 200, 300 mg/kg) was investigated in indomethacin-induced mice. The mice were induced with ulcer 6 hours prior to administration with the extract which was administered orally for 3 days. All the *Torilis leptophylla* extract treated groups had significant decrease in gastric juice volume, ulcer index, number of lesions and ulcer percentage with a significant increase in pH in comparison with the untreated group. Histopathological assessment showed improved integrity of gastric tissue in the groups administered with *Torilis leptophylla* compared with the untreated group which had erosions, vasocongestion, inflammation in the gastric tissues [46].

***Nymphaea lotus* Linn and *Nymphaea Alba* Linn:** *Nymphaea lotus*, also referred to as water lily, is utilized in treating nervous disorders, diabetes and the leaves have antioxidant properties [47]. The gastro-protective potential of the methanol extract of *N. lotus* leaves was investigated in ethanol, hypothermic stress, and indomethacin-induced ulcer rats. The rats were pre-treated with 200, 400, 600 mg/kg extract for 14 days



before ulcer induction. The anti-ulcer potential of the methanol extract was similar to the standard drug (omeprazole). The rats pre-treated with all the methanol extract doses had significantly decreased gastric ulcer indices and lesions in all gastric ulcer models. The epithelial mucosa was moderately disintegrated in rats administered 200 mg/kg of methanol extract; minor hemorrhages were observed in 400 mg/kg treated rats with no gastric lesions in the 600 mg/kg treated rats [48].

*Nymphaea alba* L. has anti-inflammatory, anti-proliferative, antioxidant properties. Ethanol extract of *Nymphaea alba* L. flower (200, 400 mg/kg) in ethanol and pylorus ligation-induced ulcer rats showed a gastric protection index of 74% and 82% respectively (pylorus ligation) and 54% and 67% respectively (ethanol-induced). In both ulcer models, 400 mg/kg treated rats had a significant increase in pH of gastric juice and reduced volume of gastric juice. The 400 and 200 mg/kg treated groups exhibited a significant reduction in the ulcer index when compared to the untreated groups [49].

**Morus alba L.:** *Morus alba* L. is also referred to as white mulberry. The leaves possess anti-inflammatory, antioxidant, and antibacterial qualities while the fruit may have neuroprotective, anti-obesity, immunomodulatory, antioxidant and antitumor activities [50-51]. Garg *et al.* [51] investigated the effect of *Morus alba* L. extract (500 mg/kg) and *Morus alba* L. (500 mg/kg) extract-loaded chitosan microsphere in ethanol-induced ulcer rats. There was a significant decrease in the gastric volume, total acidity, gastric ulcer index while pH level was significantly increased in comparison to the untreated group. Rats treated with *Morus alba* L. extract-loaded chitosan microsphere and *Morus alba* L. extract had reduced gastric lesions and improved architecture of the gastric mucosa cells.

**Magnolis Officinalis:** *Magnolis officinalis* possesses antioxidant, anti-microbial, anti-tumor, anti-inflammatory, neuroprotective and cardioprotective potentials [52]. Pretreatment of pylorus ligation-induced gastric ulcer mice with water extract of *Magnolis officinalis* (100 mg/kg) for 28 days ameliorated damage to gastric mucosa. In the extract-treated mice, there was a significant reduction in the gastric juice secretion, TNF- $\alpha$ , IL-6 levels, and ulcer index; increased gastric juice pH and CB2 gene expression (involved in reducing inflammatory responses) in comparison to the untreated group [53]. Lee *et al* [54], determined the in vivo and in vitro anti-helicobacter pylori activity of the bark of *Magnolis officinalis*. In the in vitro investigation, bark extract of *Magnolis officinalis* (100  $\mu$ g/ml) had an inhibitory effect against the *H.pylori* growth with an inhibition zone of 20.9mm, 100, 50, 25 and 12.5  $\mu$ g/ml of the extract had significant anti-adhesion activity against *H.pylori* by 90.2%, 60.5%, 45.7% and 27.5% respectively and also significantly reduced IL-8 level in the gastric epithelial cells. In the in vivo investigation, C57BL/6 *H.pylori*-infected mice were treated with 50 and 25 mg/kg bark extract of *Magnolis officinalis* for 4 weeks and significant reduction in *H.pylori* colonization, mucosal inflammation and damage to the gastric epithelial layers were observed. The gastroprotective effect of ethanol extract from magnolia officinalis bark (30, 60 and 120 mg/kg) in ethanol-induced ulcer rats was investigated and the group administered 120 mg/kg of the extract had total gastric mucosa and epithelial tissue recovery without any bleeding spots suggesting that the activity of the extract might be dose-dependent. All the doses of the extract reduced MDA level, increased GSH-Px and SOD activities and inhibited the activation of NF- $\kappa$ B signal transduction, with the high dose (120 mg/kg) having a more significant effect on oxidative stress markers

Pretreatment with 120 and 60 mg/kg significantly reduced the PGE2 level in the gastric mucosa. IL-1 $\beta$ , IL-6, TNF- $\alpha$  levels were also decreased in the extract-treated groups compared to the untreated group [55].

***Triticum aestivum* L. (Poaceae):** *Triticum aestivum* L. (wheat) is a nutrient-filled grain that has been discovered to protect against cardiovascular diseases, metabolic dysfunctions, and cancer [56]. *Triticum aestivum* aqueous extract (200, 100, 50 mg/kg) was administered to acetic acid and indomethacin-induced ulcer rats for 2 weeks, it was discovered the animals administered the extract had a dose-dependent reduction in ulcer score. The group which received 200 mg/kg extract had intact gastric epithelium with mild infiltration of inflammatory cells while those which received 100 and 50 mg/kg extract had mild erosion of gastric epithelium with mild infiltration of inflammatory cells compared with the untreated group. All doses of the *Triticum aestivum* extract significantly increased CAT and NO levels and reduced MDA levels [57]. The gastroprotective activity of 400 and 200 mg/kg *Triticum aestivum* extract was investigated by Oomen *et al.* [58] in ethanol-induced gastric ulcers in rats. There was a significant reduction in MDA levels and gastric ulcer index, while TAC, CAT and GSH levels were significantly elevated in the groups administered the extract (pre-treatment and post-treatment) compared with the untreated group. Low mucosal damage and reduced ulcer development were also observed in the extract-treated group.

***Combretum paniculatum* Vent. (Combretaceae):** *Combretum paniculatum* Vent. also known as burning bush or fire vine is known to possess cytotoxic effects on breast cancer cells, antimicrobial, and antidiarrheal activities [59-60]. Methanol extract and other fractions (ethyl acetate, butanol, n-hexane) of *C. paniculatum* (100

and 200 mg/kg) were administered to ethanol-induced ulcer rats. The extract and fractions had significant percentage protection and reduced ulcer index with the hexane fraction having the highest protection (80%) and most reduced ulcer index at 200 mg/kg. The fractions and extract significantly reduced gastric MDA levels except for the 200 mg/kg of hexane fraction which had a non-significant reduction. The fractions and extract significantly increased SOD levels except for 100 mg/kg of butanol and ethyl acetate fractions (100 and 200 mg/kg); significantly increased CAT levels except for 100 mg/kg of hexane and butanol fractions. Reduced glutathione level was significantly increased only in the methanol extract of *C. paniculatum*. The gastric mucosa of the fractions and extract-treated rats had moderate hemorrhage, normal thickness and non-congestion compared with the untreated group. The *C. paniculatum* fractions and extract-treated groups also had few areas of minimal necrosis and reduced bleeding of the gastric mucosa compared with the untreated group which had large ulcers, bleeding, infiltration of inflammatory cells, and extensive necrosis [61]. Builders *et al.* [62], evaluated the anti-ulcer potentials of methanol extract of *C. paniculatum* leaf (200, 400 and 800 mg/kg) in pylorus-ligation induced ulcer in rats. The extract significantly reduced the ulcer index and inhibited the percentage ulcer in a dose-dependent manner. There was a significant decrease in gastric volume and significant increase in gastric pH in rats administered 400 and 800 mg/kg of *C. paniculatum* compared with the untreated group. A normal stomach histology and morphology was observed in the group treated with 800 mg/kg *C. paniculatum*.

***Capparis spinosa* L. (Capparaceae):** *Capparis spinosa*, also known as wild watermelon, has been discovered to possess anti-hypertensive, anti-microbial, anti-diabetic,

anti-inflammatory, anti-hepatotoxic, antioxidant potentials [63-66]. Al-Zubaidy & Khalil [67], evaluated the gastroprotective effect of *C. spinosa* in indomethacin-induced gastric ulcer in rats. *C. spinosa* significantly reduced tissue gastrin, TNF- $\alpha$  level in the gastric mucosa and IL-1 $\beta$  expression with a significant increase in PGE2 level in the gastric mucosa in comparison to the untreated group. *C. spinosa* also significantly reduced epithelial erosion.

**Basella Alba L. (Basellaceae):** *Basella Alba L.*, also known as Malabar spinach, contains triterpene, betacyanins, carotenoids, and vitamins and it has been discovered to possess anti-inflammatory, antioxidant, antibacterial, nephroprotective, and CNS depressant activities [68]. The anti-ulcer effect of 100, 200, and 400 mg/kg ethanol extract of *Basella alba* was investigated in aspirin and pyloric ligation-induced ulcer in rats. The extract had a dose-dependent gastroprotective effect. There was a significant decrease in gastric volume, ulcer index and acidity while gastric pH and percentage protection were significantly increased with the 400 mg/kg dose exhibiting the highest effect in both the aspirin and pyloric ligation-induced ulcer models [69].

**Glycyrrhiza glabra L.:** *Glycyrrhiza glabra* is also known as sweet wood, licorice and it contains flavonoids, saponins, tannins, and phytosterols [70]. *G. glabra* has been reported to have antioxidant, anti-inflammatory, neuroprotective, anticancer, antimutagenic, hepatoprotective, and antimicrobial activities [71-75]. The effect of 100 mg/kg (low dose) and 200 mg/kg (high dose) aqueous licorice extract on stress-induced gastric ulcer in rats was investigated and a dose-dependent effect was observed with the high dose showing an almost normal gastric mucosa. The licorice-treated group had a lower ulcer index and reduced inflammation compared to the untreated group [76]. Pre-

administration of turmeric rhizome and licorice aqueous extract (200 and 500 mg/kg) in ethanol-induced gastric ulcer increased the pH of gastric juice, significantly decreased COX-2, Bax level, ulcer areas, and number of gastric lesions compared to the ulcer-untreated group with 500 mg/kg exhibiting the highest effect. The 200 and 500 mg/kg extract had a protective index of 68% and 82%, respectively [77].

**Zingiber officinale:** This is commonly referred to as ginger and it contains bioactive compounds including steroids, phenolics (gingerol), phenylalkanooids, sulfonates, alkaloids, and xanthenes (78). It possesses neuroprotective, cardioprotective, hepatoprotective, anti-cancer, hypolipidemic, and antidiabetic activities [79-83]. Airaodion *et al.* [84], investigated the antiulcer effect of aqueous extract of *zingiber officinale* in indomethacin-induced ulcer in albino rats for 7 and 14 days. The ulcer index was significantly reduced (29.67 and 28.28) and % ulcer inhibition were significantly increased (57.51% and 59.90%) in the 7 and 14 day groups respectively compared to the untreated group. Steamed golden ginger extract (10, 30, 100, 300 mg/kg) was orally administered to ethanol/HCL-induced ulcer rats and this resulted in a significant decrease in gastric ulcer lesions in the 100 and 300 mg/kg ginger treated group. Treatment with 100 mg/kg ginger extract significantly reduced acute gastric ulcer formation and restored nitric oxide. There was a significant increase in GSH, CAT, and SOD levels and reduced MDA, myeloperoxidase, NF- $\kappa$ B, IL-1 $\beta$ , and TNF- $\alpha$  levels in the 100 mg/kg ginger-treated group [85].

## CONCLUSION

The prevalence of peptic ulcer disease in the global population is 5-10% and the risk factors are *H. pylori* infection, NSAIDs, alcohol and tobacco consumption.

Medicinal plants have been proven to be potent and effective in preventing and treating various diseases including peptic ulcer. This review therefore enumerated the mechanisms of action of some medicinal plants which include increased antioxidant activities, gastric pH, reduced gastric index and total acidity, minimal necrosis, and improved gastric morphology. However, more studies should be carried out to determine the active compounds in these plants. Human clinical trials are also needed to validate the safety and efficacy of these medicinal plants since most of the studies enumerated in this review are animal-based studies.

**Abbreviations:** TNF  $\alpha$ : Tumor necrosis factor- $\alpha$ , IL-6: Interleukin-6, IL-1 $\beta$ : Interleukin-1 beta, LDL: Low density lipoprotein, GSH: Glutathione, CAT: Catalase, TC: Total cholesterol, PPI: proton pump inhibitors, PUD: Peptic ulcer disease, MDA: Malondialdehyde, SOD: Superoxide dismutase, AST: Alanine Aminotransferase, ALT: Aspartate Transferase, COX-2: Cyclooxygenase-2, NO: Nitric oxide, TAC: Total antioxidant capacity.

**Competing interests:** The authors have no financial interests or conflicts of interest. Authors' contribution: All authors contributed to this study.

**Acknowledgement and Funding:** No funding was received for this review.

## REFERENCES

- Zatorski H. Pathophysiology and Risk Factors in Peptic Ulcer Disease. *Introduction to Gastrointestinal Diseases* 2017, 2(2): 7–20. DOI: [https://doi.org/10.1007/978-3-319-59885-7\\_2](https://doi.org/10.1007/978-3-319-59885-7_2)
- Bereda G. Definition, Pathophysiology, and Treatment. *Journal of Biomedical and Biological Sciences* 2022, 2: 1–10.
- Taha MME, Abdelwahab SI, Mariod, A, Abdulla MA, Nordin N, Jayapalan JJ, Hashim OH. Stem bark methanolic extract of *Bauhinia thonningii* (Schum) demonstrates gastroprotective

properties against in vivo ethanol-induced injury. *Functional Food Science* 2023, 3(4): 26–40. DOI: <https://doi.org/10.31989/ffs.v3i4.1048>.

- Prabhu V, Shivani A. An overview of history, pathogenesis and treatment of perforated peptic ulcer disease with evaluation of prognostic scoring in adults. *Annals of medical and health sciences research* 2014, 4(1): 22–29. DOI: <https://doi.org/10.4103/2141-9248.126604>
- Kuna L, Jakab J, Smolic R, Raguz-Lucic N, Vcev A, Smolic M. Peptic Ulcer Disease: A Brief Review of Conventional Therapy and Herbal Treatment Options. *Journal of clinical medicine* 2019, 8(2): 179. DOI: <https://doi.org/10.3390/jcm8020179>.
- Narayanan M, Reddy KM, Marsicano E. Peptic ulcer disease and *Helicobacter pylori* infection. *Missouri medicine* 2018, 115(3): 219.
- Zarchi SR, Dousti M, Rezazadeh D, Sajadi E, Rizvand S, Roozbahani NE. Mechanism Prediction of Gastro-protective Effects of the *Biebersteinia multifida* against Ethanol-Induced Gastric Ulcers; an Insilco study. *Functional Foods in Health and Disease* 2022, 12(9): 518–533. DOI: <https://doi.org/10.31989/ffhd.v12i9.964>.
- Siddique O, Ovalle A, Siddique AS, Moss SF. *Helicobacter pylori* infection: An update for the internist in the age of increasing global antibiotic resistance. *Am. J. Med.* 2018, 131: 473–479. DOI: <https://doi.org/10.1016/j.amjmed.2017.12.024>.
- Fornai M, Antonioli, L, Rocchina C, Marco T, Blandizzi C. Pathophysiology of gastric ulcer development and healing: molecular mechanisms and novel therapeutic options. *In Peptic ulcer disease* 2011, 113–142.
- Bi WP, Man HB, Man MQ. Efficacy and safety of herbal medicines in treating gastric ulcers: a review, *World J. Gastroenterol* 2014, 20(45): 17020–17028. DOI: <https://doi.org/10.3748/wjg.v20.i45.17020>.
- Ighodaro OM, Akinloye OA. First line defence antioxidants-superoxide dismutase (SOD), catalase (CAT) and glutathione peroxidase (GPX): Their fundamental role in the entire antioxidant defence grid, *Alex. J. Med.* 2018, 54 (4): 287–293, DOI: <https://doi.org/10.1016/j.ajme.2017.09.001>.
- Adebayo-Gege G, Uthman ZS, Adams MD, Florence T, Haruna DU, Audu NM, Lawan HJ, Queen O, Chinedu O, Meraiyebu A, Kafaru, O. Molecular docking and anti-ulcerative potential of *Cucumis* (L. Inodorous) on ibuprofen

- induced gastric ulceration in male wistar animals. *Biomedicine and Pharmacotherapy* 2023, 161: 114531. DOI: <https://doi.org/10.1016/j.biopha.2023.114531>.
13. Bouaziz A, Bentahar A, Djidel S, Dahamna S, Khennouf S. In vitro antioxidant activity and gastroprotective effect of ethanolic extract from *Cucumis melo* L. var. inodorus fruit on ethanol-induced gastric ulcer in rats. *Journal of Drug Delivery and Therapeutics* 2020, 10(5-s): 302-307. DOI: <https://doi.org/10.22270/jddt.v10i5-s.4529>.
  14. Adebayo-Gege GI. Protective Functions of Methanol Extract of *Cucumis Melo* (L. Inodorous) seeds on Pyloric ligation induced gastric ulceration in male Wistar rats. *Magna Scientia Advanced Research and Reviews* 2023, 8(01): 102–113. DOI: <https://doi.org/10.30574/msarr.2023.8.1.0076>.
  15. Pasandi Pour A, Farahbakhsh H. Lawsonia inermis L. leaves aqueous extract as a natural antioxidant and antibacterial product. *Natural product research* 2020, 34(23): 3399-3403. DOI: <https://doi.org/10.1080/14786419.2019.1569006>.
  16. Khatun R, Khanam F, Juhi SA, Khatune NA, Rahman, MAA. In vitro evaluation of anti-diabetic and anti-inflammatory activities of ethanolic extract of Lawsonia inermis L. leaves (Family: Lythraceae). *Journal of Pharmacognosy and Phytochemistry* 2022, 11(1): 252-255.
  17. Moutawalli A, Benkhouili FZ, Doukkali A, Benzeid H, Zahidi A. The biological and Pharmacologic Actions of *Lawsonia inermis* L. *Phytomedicine Plus* 2023, 100468. DOI: <https://doi.org/10.1016/j.phyplu.2023.100468>.
  18. Mohammed DM, Ahmed KA, Desoukey MA, Sabry BA. Assessment of the antiulcer properties of Lawsonia inermis L. leaves and its nano-formulation against prolonged effect of acute ulcer in rats. *Toxicology Reports* 2022, 9: 337-345. DOI: <https://doi.org/10.1016/j.toxrep.2022.03.010>.
  19. Adinortey MB, Ansah C, Adinortey CA, Bockarie AS, Morna MT, Amewowor DH. Isolation of Helicobacter pylori from gastric biopsy of dyspeptic patients in Ghana and in vitro preliminary assessment of the effect of Dissotis rotundifolia extract on its growth. *Journal of Tropical Medicine* 2018, 8071081. DOI: <https://doi.org/10.1155/2018/8071081>.
  20. Adinortey MB, Ansah C, Aboagye B, Sarfo JK, Martey O, Nyarko AK. Flavonoid-Rich Extract of Dissotis rotundifolia Whole Plant Protects against Ethanol-Induced Gastric Mucosal Damage. *Biochemistry Research International*, 2020, 7656127. DOI: <https://doi.org/10.1155/2020/7656127>.
  21. Adinortey MB, Ansah C, Asiedu-Larbi J, Kwofie SK, Bockarie AS, Barnes P, Aboagye B, Helegbe GK, Boison D, Nyarko AK. In vivo inhibition of gastric acid secretions and H<sup>+</sup>/K<sup>+</sup>-ATPase activity, and enhancement of mucin activity by Dissotis rotundifolia plant extract. *Scientific African* 2022, 17: e01317. DOI: <https://doi.org/10.1016/j.sciaf.2022.e01317>.
  22. Pienaar L, Barends-Jones V. The economic contribution of South Africa's pomegranate industry. *Agriprobe* 2021, 18(4): 57-64.
  23. Mphahlele RR, Fawole OA, Makunga NP, Opara UL. Effect of drying on the bioactive compounds, antioxidant, antibacterial and antityrosinase activities of pomegranate peel. *BMC complementary and alternative medicine* 2016, 16(1): 1-12. DOI: <https://doi.org/10.1186/s12906-016-1132-y>.
  24. Melgarejo-Sánchez P, Núñez-Gómez D, Martínez-Nicolás JJ, Hernández F, Legua P, Melgarejo P. Pomegranate variety and pomegranate plant part, relevance from bioactive point of view: A review. *Bioresources and Bioprocessing* 2021, 8: 1-29. DOI: <https://doi.org/10.1186/s40643-020-00351-5>.
  25. Wang D, Özen C, Abu-Reidah IM, Chigurupati S, Patra JK, Horbanczuk JO, Józwik A, Tzvetkov NT, Uhrin P, Atanasov AG. Vasculoprotective effects of pomegranate (*Punica granatum* L.). *Frontiers in pharmacology* 2018, 9: 544. DOI: <https://doi.org/10.3389/fphar.2018.00544>.
  26. Wafa BA, Makni M, Ammar S, Khannous L, Hassana AB, Bouaziz M, Es-Safi NE, Gdoura R. Antimicrobial effect of the Tunisian Nana variety *Punica granatum* L. extracts against *Salmonella enterica* (serovars Kentucky and Enteritidis) isolated from chicken meat and phenolic composition of its peel extract. *International journal of food microbiology* 2017, 241: 123-131. DOI: <https://doi.org/10.1016/j.ijfoodmicro.2016.10.007>.
  27. Pottathil S, Nain P, Morsy MA, Kaur J, Al-Dhubiab BE, Jaiswal S, Nair AB. Mechanisms of antidiabetic activity of methanolic extract of punica granatum leaves in nicotinamide/streptozotocin-induced type 2 diabetes in rats. *Plants* 2020, 9(11): 1609. DOI: <https://doi.org/10.3390/plants9111609>.
  28. Wong TL, Strandberg KR, Croley CR, Fraser SE, Venkata KCN, Fimognari C, Sethi G, Bishayee, A. Pomegranate bioactive constituents target multiple oncogenic and oncosuppressive signaling for cancer prevention and intervention.

- In Seminars in Cancer Biology 2021, 73: 265-293. Academic Press.
29. Lydia DE, Khusro A, Immanuel P, Esmail GA, Al-Dhabi NA, Arasu MV. Photo-activated synthesis and characterization of gold nanoparticles from Punica granatum L. seed oil: An assessment on antioxidant and anticancer properties for functional yoghurt nutraceuticals. Journal of Photochemistry and Photobiology Biology 2022, 206: 111868. DOI: <https://doi.org/10.1016/j.jphotobiol.2020.111868>.
  30. Islam AR, Ferdousi J, Shahinozzaman M. Previously published ethno-pharmacological reports reveal the potentiality of plants and plant-derived products used as traditional home remedies by Bangladeshi COVID-19 patients to combat SARS-CoV-2. Saudi Journal of Biological Sciences 2021, 28(11): 6653-6673. DOI: <https://doi.org/10.1016/j.sjbs.2021.07.036>.
  31. Wong TL, Strandberg KR, Croley CR, Fraser SE, Venkata KCN, Fimognari C, Sethi G, Bishayee A. Pomegranate bioactive constituents target multiple oncogenic and oncosuppressive signaling for cancer prevention and intervention. In Seminars in Cancer Biology. Academic Press 2021, 73:265-293. DOI: <https://doi.org/10.1016/j.semcan.2021.01.006>.
  32. Ahmed JT, Alibraheem S, Tareh FJ, Mhalhal, SL. Evaluate the Anti-Ulcer Activity of Pomegranate Peel Powder (*Punica granatum*) In local Rabbits Infected by Aspirin-induced Peptic Ulcer. International Journal of Pharmaceutical Research 2020, 12(3). DOI: <https://doi.org/10.31838/ijpr/2020.12.03.422>.
  33. Piracha MI, Alam SS, Farooq H, Zulfiqar T, Khan FA, Zahra MEN. Prophylactic Anti-Ulcer Effect of Punica Granatum (Pomegranate) Peel and Seed Extract in Murine Peptic Ulcer Model. Esculapio Journal of SIMS 2022, 18(4):495-499. DOI: <https://doi.org/10.51273/esc22.2518420>.
  34. Muhiyaldin AJ, Alamri ZZ, Hussein AM, Faraj RK, Taha ZB, Hussein MM, Mojarradgandoukmolla S. Gastro-Protective and Therapeutic Effect of Punica granatum against Stomach Ulcer Caused by Helicobacter Pylori. Cellular and Molecular Biology 2023, 69(1):48-53. DOI: <https://doi.org/10.14715/cmb/2022.69.1.9>.
  35. Ashande CM, Lufuluabo GL, Mukiza J, Mpiiana PT. A mini-review on the Phytochemistry and Pharmacology of the medicinal plant species Persea americana Mill. (Lauraceae). Discovery Phytomedicine 2019, 6(3):102-111. DOI: <http://dx.doi.org/10.15562/phytomedicine.2019.99>.
  36. Bhore SJ, Ochoa DS, Al Houssari A, Zelaya AL, Yang R, Chen Z, Deeya SS, da Silva Sens SC, Schumann M, Zhang Z, Eltantawy, E. The Avocado (*Persea americana* Mill.): A Review and Sustainability Perspectives 2021, 2021120523. DOI: <https://doi.org/10.20944/preprints202112.0523.v1>.
  37. Umeh VN, Akah PA, Okoyeh JN, Orji CE. Ulcer-healing Effects of *Persea Americana* (avocado) seeds. World Journal of Pharmacy and Pharmaceutical Sciences 2021, 12(10):48-64.
  38. Salawu MO, Shittu A, Nafiu MO, Oloyede, HOB. Gastroprotective potentials of aqueous extract of *Persea americana* seed against Aspirin-induced ulcer in Wistar rats. Biokemistri 2020, 32(1): 35-46.
  39. Offor S, Tologbonse AA, Akpan SOJ, Anah VU, Edward EA. Evaluation of the Anti-ulcer Effect of Extra Virgin Avocado (*Persea americana*) Oil in Rats. European Journal of Pharmaceutical Research 2022, 2(1):1-5. DOI: <https://doi.org/10.24018/ejpharma.2022.2.1.15>.
  40. Athaydes BR, Tosta C, Carminati RZ, Kuster RM, Kitagawa RR, Gonçalves RDCR. Avocado (*Persea americana* Mill.) seeds compounds affect *Helicobacter pylori* infection and gastric adenocarcinoma cells growth. Journal of Functional Foods 2022, 99:105352. DOI: <https://doi.org/10.1016/j.jff.2022.105352>.
  41. Abd Allah AL. Anti-ulcer Activity of Avocado Juice and Kiwi Juice on Indomethacin Induced Gastric Ulcer in Rats. Egyptian Journal of Nutrition and Health 2019, 14(2):27-44. DOI: <https://doi.org/10.21608/einh.2019.104050>.
  42. Osuala FN, Fagbenja KS, Mounmbegna PP. Pharmacognostic and antidysentery screening of mixed ethanol leaf extract of *Parkia biglobosa* and *Acanthus montanus* (50: 50). Magna Scientia Advanced Research and Reviews 2021, 3(2): 017-039. DOI: <https://doi.org/10.30574/msarr.2021.3.2.0073>.
  43. Okorie NH, Ali IJ, Nnadi CO, Ani DI. Anti-ulcer Activity of Crude Extract and Fractions of *Acanthus montanus* (Nees) T. Anderson on Indomethacin-Induced Ulcer. Trop J Nat Prod Res 2023, 7(5): 3017-3021. DOI: <http://www.doi.org/10.26538/tjnpr/v7i5.26>.
  44. Fatima J, Shaheen B, Batool S, Malik T, Qammar SM, Naureen S. Evaluation of anti-arthritis effect of *Torilis leptophylla* and its comparison with indomethacin. Journal of Fatima Jinnah Medical University 2020, 14(1): 25-29.

45. Fang Y, Lv L, Chai YJ, Yu F. Neuroprotective effect of whole-plant extract of *Torilis leptophylla* in isoflurane-treated rats. *Tropical Journal of Pharmaceutical Research* 2016, 15(12): 2571-2578. DOI: <https://doi.org/10.4314/tjpr.v15i12.6>.
46. Batool S, Qammar SM, Malik T, Ahmad NS, Shaheen B, Fatima J. Anti-Ulcerogenic Evaluation of *Torilis Leptophylla* Plant Extract on Indomethacin Induced Mice Gastric Ulcer. In *Proceedings* 2022, 36(4): 51-58. DOI: <https://doi.org/10.47489/pszmc8573645158>.
47. Aliyu M, Atiku M, Abdullahi N, Zaharaddeen A, Imam A. Comparative evaluation of nutritional qualities of *Nymphaea lotus* and *Nymphaea pubescens* seeds. *International Journal of Biochemistry Research & Review* 2017, 19(3): 1-10.
48. Aliyu M, Abdulrauf MS, Ganiyu AI. Evaluation of the Gastro-protective Potentials of Methanol Leaf Extract of *Nymphaea lotus* on Induced-Gastric Ulceration in Wistar Rats. *Nigerian Journal of Life Sciences* 2022, (ISSN: 2276-7029), 12(2): 1-6.
49. Paharia AK, Pandurangan A. Evaluation of Anti-ulcer activity of Ethanolic Extract of *Nymphaea Alba* Linn Flower in experimental rats. *American Journal of Pharmtech Research* 2020, 10(1): 1-14.
50. Yuan Q, Zhao L. The Mulberry (*Morus alba* L.) Fruit: A Review of Characteristic Components and Health Benefits. *Journal of Agricultural and Food Chemistry* 2017, 65(48): 10383-10394. DOI: <https://doi.org/10.1021/acs.jafc.7b03614>.
51. Garg S, Singla RK, Rahman MM, Sharma R, Mittal V. Evaluation of ulcer protective activity of *morus alba* L. Extract-loaded chitosan microspheres in ethanol-induced ulcer in rat model. *Evidence-Based Complementary and Alternative Medicine*, 2022. Article ID 4907585. DOI: <https://doi.org/10.1155/2022/4907585>.
52. Luo H, Wu H, Yu X, Zhang X, Lu Y, Fan J, Tang L, Wang Z. A review of the phytochemistry and pharmacological activities of *Magnoliae officinalis* cortex. *Journal of ethnopharmacology* 2019, 236: 412-442. DOI: <https://doi.org/10.1016/j.jep.2019.02.041>.
53. Shen KP, Chang CD, Hsieh MH, Chaung HC. Efficiency and Mechanism Evaluation of *Magnolia officinalis* Water Extract in Preventing Gastric Ulcer. *Evidence-Based Complementary and Alternative Medicine* 2023, Article ID 7901734. DOI: <https://doi.org/10.1155/2023/7901734>.
54. Lee HA, Hong S, Yoo JH, Kim O. Anti-Helicobacter pylori activity and inhibition of gastritis by *Magnolia officinalis* extract. *The Thai Journal of Veterinary Medicine* 2018, 48(2): 203-210. DOI: <https://doi.org/10.56808/2985-1130.2903>.
55. Wang X, Fu S, Zhang C, Nie X, Liao W, Zhao M, Liu F. Gastroprotective effect of ethanol extracts from bark of *Magnolia officinalis* on ethanol-induced gastric mucosal damage in rats. *BioMed Research International*, 2021: 1-13. DOI: <https://doi.org/10.1155/2021/6688414>.
56. Moshawih S, Abdullah Juperi R.A.N.A, Paneerselvam GS, Ming LC, Liew KB, Goh BH, Al-Worafi YM, Choo CY, Thuraisingam, S, Goh HP, Kifli N. General health benefits and pharmacological activities of *Triticum aestivum* L. *Molecules* 2022, 27(6): 1948. DOI: <https://doi.org/10.3390/molecules27061948>.
57. Adebayo-Gege GI, Adetomiwa DA, Omayone TP, Akintayo OC, Ozegbe QB, Dimeji IY, Ojo OA. Anti-ulcer potentials of aqueous extract of *Triticum aestivum* on delayed healing of experimentally induced/gastric ulcer. *Nigerian Journal of Experimental and Clinical Biosciences* 2022, 10(3): 90-97. DOI: [https://doi.org/10.4103/njecp.njecp\\_13\\_22](https://doi.org/10.4103/njecp.njecp_13_22).
58. Oomen SS, Fernandes H, Holla R. Gastroprotective effects of *Triticum aestivum* Linn., extract on ethanol-induced gastric ulcer in Wistar rats. *Biomedicine* 2022, 42(6): 1216-1222. DOI: <https://doi.org/10.51248/v42i6.2046>.
59. Birhanu B, Fikre M, Milkyas E, Addisu D. Phenolic glycoside and steroid from the roots of *Combretum Paniculatum*. *J Nat Sci Res* 2018, 8: 15.
60. Peter IE, Aroh CM, Shere UG, Ani NI, Adaka IC, Asogwa FK, Isiogugu ON, Abonyi CU, Onwuka AM. Pharmacological Actions of Methanol Leaf Extract of *Combretum paniculatum* Vent.(Combretaceae) on the Gastrointestinal System: *Tropical Journal of Natural Product Research* 2020, 4(7): 270-275.
61. Emmanuel PI, Sandra UC, Marytheresa OA., Nwakaego MF, Nneoma OM, Azubuike O C, Uzor PF. Gastroprotective effects of *Combretum paniculatum* (Combretaceae) leaf extract and fractions on absolute ethanol-induced gastric ulcer in rats. *Future Journal of Pharmaceutical Sciences* 2022, 8(1): 1-11. DOI: <https://doi.org/10.1186/s43094-022-00442-4>.
62. Builders MI, Udeh BO, Ede SO, Joseph SO, Ise PU. Evaluation of anti-ulcer activity of methanolic extract *Combretum paniculatum* Vent. in rats and mice using pylorus-ligation

- induced model. Open Access Research Journal of Life Sciences 2023, 5(2): 010–020. DOI: <https://doi.org/10.53022/oarjms.2023.5.2.0023>.
63. El Azhary K, Tahiri Jouti N, El Khachibi M, Moutia, M, Tabyaoui I, El Hou A, Achtaq H, Nadifi S, Habti N, Badou A. Anti-inflammatory potential of Capparis spinosa L. in vivo in mice through inhibition of cell infiltration and cytokine gene expression. BMC complementary and alternative medicine 2017, 17: 1-12. DOI: <https://doi.org/10.1186/s12906-017-1569-7>.
  64. Mazarei F, Jooyandeh H, Noshad M, Hojjati M. Polysaccharide of caper (Capparis spinosa L.) Leaf: Extraction optimization, antioxidant potential and antimicrobial activity. International journal of biological macromolecules 2017, 95: 224-231. DOI: <https://doi.org/10.1016/j.ijbiomac.2016.11.049>.
  65. Rahnavard R, Razavi N. A review on the medical effects of Capparis spinosa L. Advanced Herbal Medicine 2017, 3(1): 44-53.
  66. Zhang H, Ma ZF. Phytochemical and pharmacological properties of Capparis spinosa as a medicinal plant. Nutrients 2018, 10(2): 116. DOI: <https://doi.org/10.3390/nu10020116>.
  67. Al-Zubaidy AA, Khalil AM. Gastroprotective effect of capparispinosa on indomethacin-induced gastric ulcer in rats. Archives of Razi Institute 2022, 77(4): 1437-1445. DOI: <https://doi.org/10.22092/ari.2022.357514.2053>.
  68. Khanom B, Nahida U, Shapla SS, Akter MS, Farzana H, Zaman F, Islam MT. Phytochemical and pharmacological review on Basella alba L. Pharmacol. Online 2019, 1: 40-48.
  69. Mohanty I, Mahapatra S, Panigrahi A, Panigrahi, G. Activity of Basella alba in the Protection of Peptic Ulcer on Experimental Rat Model. Research Journal of Pharmacy and Life Sciences 2021, 2(1): 78-87.
  70. Rizzato G, Scalabrin E, Radaelli M, Capodaglio G, Piccolo, O. A new exploration of licorice metabolome. Food Chemistry 2017, 221: 959-968. DOI: <https://doi.org/10.1016/j.foodchem.2016.11.068>.
  71. Chakotiya AS, Tanwar A, Srivastav, P, Narula, A, Sharma RK. Effect of aquo-alcoholic extract of Glycyrrhiza glabra against Pseudomonas aeruginosa in mice lung infection model. Biomedicine and Pharmacotherapy 2017, 90: 171–178. DOI: <https://doi.org/10.1016/j.biopha.2017.03.055>.
  72. Wang XR, Hao HG, Chu L. Glycyrrhizin inhibits LPS-induced inflammatory mediator production in endometrial epithelial cells. Microbial pathogenesis 2017, 109: 110-113. DOI: <https://doi.org/10.1016/j.micpath.2017.05.032>.
  73. Yang R, Yuan BC, Ma YS, Zhou S, Liu Y. The anti-inflammatory activity of licorice, a widely used Chinese herb. Pharmaceutical biology 2017, 55(1): 5-18. DOI: <https://doi.org/10.1080/13880209.2016.1225775>.
  74. Yin X, Gong X, Zhang L, Jiang R, Kuang G, Wang B, Chen X, Wan J. Glycyrrhetic acid attenuates lipopolysaccharide-induced fulminant hepatic failure in d-galactosamine-sensitized mice by up-regulating expression of interleukin-1 receptor-associated kinase-M. Toxicology and Applied Pharmacology, 2017: 320:8-16. DOI: <https://doi.org/10.1016/j.taap.2017.02.011>.
  75. Pastorino G, Cornara L, Soares S, Rodrigues F, Oliveira MBP. Liquorice (Glycyrrhiza glabra): A phytochemical and pharmacological review. Phytotherapy research 2018, 32(12): 2323-2339. DOI: <https://doi.org/10.1002/ptr.6178>.
  76. Mathur S, Philipose CS, Ganaraja B. Effect of aqueous extract of liquorice (G. Glabra L) in treatment of stress induced gastric ulcer in Wistar rats. Pharmacognosy Journal 2019, 11(6s): 1526-1531. DOI: <http://dx.doi.org/10.5530/pj.2019.11.233>.
  77. Panji M, Ghafouri M. Evaluation of Gastroprotective Activity of Licorice and Turmeric Rhizome Aqueous Extract against Ethanol-Induced Gastric Injury in Male Wistar Rats. Medical Laboratory Journal 2022, 16(4): 32-38. DOI: <http://dx.doi.org/10.52547/mlj.16.4.32>.
  78. Chaiyasit K, Tokaew W, Boonsiri K. Medicinal plants and the communication on precautionary use of herbs during COVID-19 outbreak in Thailand. Bioactive Compounds in Health and Disease 2021, 4(8), 180-188. DOI: <https://www.doi.org/10.31989/bchd.v4i8.825>.
  79. Na JY, Song K, Lee JW, Kim S, Kwon J. Pretreatment of 6-shogaol attenuates oxidative stress and inflammation in middle cerebral artery occlusion-induced mice. European Journal of Pharmacology 2016, 788: 241–247. DOI: <https://doi.org/10.1016/j.ejphar.2016.06.044>.
  80. Zhang F, Thakur K, Hu F, Zhang JG, Wei ZJ. 10-Gingerol, a phytochemical derivative from Tongling white ginger, inhibits cervical cancer: Insights into the molecular mechanism and inhibitory targets. Journal of Agricultural and Food Chemistry 2017, 65(10): 2089–2099. DOI: <https://doi.org/10.1021/acs.jafc.7b00095>.



81. Vipin AV, Raksha RK, Nawneet KK, Appaiah Anu KA, Venkateswaran G. Protective effects of phenolics rich extract of ginger against Aflatoxin B1-induced oxidative stress and hepatotoxicity. *Biomedicine & Pharmacotherapy* 2017, 91: 415–424. DOI: <https://doi.org/10.1016/j.biopha.2017.04.107>.
82. Wei CK, Tsai YH, Korinek M, Hung PH, El-Shazly M, Cheng YB, Wu YC, Hsieh TJ, Chang FR. 6-Paradol and 6-shogaol, the pungent compounds of ginger, promote glucose utilization in adipocytes and myotubes, and 6-paradol reduces blood glucose in high-fat diet-fed mice. *International journal of molecular sciences* 2017, 18(1):168. DOI: <https://doi.org/10.3390/ijms18010168>.
83. Zhang M, Zhao R, Wang D, Wang L, Zhang Q, Wei S, Lu F, Peng W, Wu C. Ginger (*Zingiber officinale* Rosc.) and its bioactive components are potential resources for health beneficial agents. *Phytotherapy Research*, 2021, 35(2):711-42. DOI: <https://doi.org/10.1002/ptr.6858>.
84. Airaodion AI, Ogbuagu U, Ogbuagu EO, Airaodion EO, Agunbiade AP, Oloruntoba AP, Mokelu IP, Ekeh SC. Investigation of aqueous extract of *Zingiber officinale* root potential in the prevention of peptic ulcer in albino rats. *International Journal of Research and Innovation in Applied Science* 2019, 4(2):64-7.
85. Shin JK, Park JH, Kim KS, Kang TH, & Kim HS Antiulcer activity of steamed ginger extract against ethanol/HCl-induced gastric mucosal injury in rats. *Molecules* 2020, 25(20): 4663. DOI: <https://doi.org/10.3390/molecules25204663>.